



Determining the effects of deviated nasal septum on maxillary sinus volume using cone-beam computed tomography

Mahshid Razavi¹, Nasim Shams¹, Seyed Mohammad Ali Pirasteh¹

Department of Oral and Maxillofacial Radiology, School of Dentistry, Ahvaz Jundishapur University of Medical Sciences, Ahvaz, Iran

*Correspondence to

Seyed Mohammad Ali
Pirasteh, Email: smapirasteh@
chmail.ir

Received 27 May 2022

Accepted 11 July 2022

Published online 18 Sep. 2022

Keywords: Maxillary sinus
volume, Nasal septum
deviation, Concha bullosa,
Cone-beam CT

Abstract

Introduction: Paranasal sinuses are four air-filled spaces in face. The maxillary sinuses are important for dentist because of their location. The volume of them can be affected by various factors and make them prone to sinusitis.

Objectives: This retrospective study examined maxillary sinus volume in relationship with nasal septum deviation (NSD) by using cone-beam computed tomography (CBCT).

Materials and Methods: From our CBCT archives, we retrospectively selected 210 CBCT images and 420 healthy maxillary sinuses. The maxillary sinuses were calculated using the NNT Viewer software by importing CBCT images. In this study, NSDs were classified into three levels of severity: mild, moderate, and severe. In patients with NSD, bilateral sinus volumes were compared and allowed us to determine the difference in maxillary sinus volume. Statistical analysis was conducted using SPSS ($P < 0.05$).

Results: The average volume of the right and left maxillary sinuses is $13.04 \pm 3.37 \text{ cm}^3$ and $13.59 \pm 3.33 \text{ cm}^3$, respectively. The prevalence of NSD in population of this study was 89.5%. Both sides of the maxillary sinuses were significantly larger in male patients than female patients ($P < 0.05$). The negative correlation between age and maxillary sinus volume ($P < 0.05$) showed that maxillary sinus volume decreased with age. For cases of moderate and severe NSDs in the same direction as the deviation, the maxillary sinus volume is significantly smaller than that on the opposite side ($P < 0.05$), while there was no significant difference in mild cases of deviation ($P > 0.05$).

Conclusion: In moderate and severe groups, maxillary sinus volume was smaller on the same side compared with the opposite side of deviation, and maxillary sinus volume is greater in male patients than female patients, and it decreases with age.

Citation: Razavi M, Shams N, Pirasteh SMA. Determining the effects of deviated nasal septum on maxillary sinus volume using cone-beam computed tomography. Immunopathol Persa. 2023;9(1):e34427. DOI:10.34172/ipp.2022.34427.



Introduction

Within the bones of the face are the paranasal sinuses, which are empty spaces filled with air. Human paranasal sinuses include maxilla, ethmoid, frontal and sphenoid. In a healthy person, each of them fills with air and an ostium connects the nasal lumen to the sinuses. Their final growth and form show many variations, and everyone can have different sinus formation (1). Dentists pay attention to the maxillary sinus because it is adjacent to teeth and relevant structures (2). Maxillary sinuses have an average volume of $6\text{--}8 \text{ cm}^3$ at birth. At five months after birth, it can be diagnosed by radiography in a standard anterior-posterior view. Lateral and inferior sinus pneumatization continues in two periods and rapidly grows from birth to third year, then again between 7 and 12 years (1).

Nasal septum deviation (NSD) is a common finding that is diagnosed by an otorhinolaryngology, but it is usually not specified on the basis of visual measurement. Due to this finding, diagnosing the disease

Key point

Maxillary sinus volume can change its size due to various factors. Deviation of the nasal septum can be one of these factors and can cause sinus disorders.

may differ substantially; its clinical effects are assessed among observers, including its precise location, quantification of deviations, and clinical assessment of its effects (3).

Patients can experience complications following surgery as a result of this objectivity (4). Most nasal deformities are caused by congenital or acquired NSDs. A recent study analyzing NSD in infants found that the rate of NSD was 22% in children with vaginal delivery, while only 4% NSD was observed in children with cesarean delivery (4). Adults with NSD can experience nasal peeling, epistaxis (nosebleeds), and sinusitis, which depends on disease severity and position. Suffocation caused by trapped food in the respiratory tract can occur in infants with severe and bilateral NSD studies of patients

with NSD-induced nasal obstruction reported retraction of the maxilla and mandible with a larger overjet and a deficiency of the maxillary transverse (5). Septal displacement increases the likelihood of stuffy nose and can affect pronunciation, beauty, and voice breathing. In addition, it can cause sinusitis, upper respiratory tract and middle ear infections (3).

Furthermore, the lack of airflow causes low-oxygen pressure, thereby interrupting the growth of the paranasal sinus, decreasing cilia motility, and finally facilitating the growth of bacteria. Despite the general belief that volume differences are associated with sinusitis, few studies have pointed that septum deviation and maxillary sinus volume are involved in pathogenesis of sinusitis (6). Many antibiotics are prescribed annually for treating chronic sinusitis, and many patients are clinically refractory and surgically relapse. However, it is unclear what role microorganisms actually play in many of these patients. Many immunocompetent patients with chronic sinusitis have the underlying anatomical etiology of their disease, such as obstruction of osteomeatal unit or NSD, a significant proportion of these patients. Despite surgical and antibiotic treatment, patients continue to suffer from chronic sinusitis (7).

Anatomical variations and pathologies associated with the paranasal sinuses can be diagnosed by a variety of imaging techniques. Cone-beam computed tomography (CBCT) is an image processing technique in the field of oral and maxillofacial radiology used to visualize three-dimensional structures. Otolaryngologists, general dentists, and dental radiologists have taken advantage of CBCT for the diagnosis of paranasal sinusitis and aligned the sinuses (8).

Compared to multislice computed tomography, CBCT has several advantages on nasal cavity and paranasal sinuses, such as easier image capture, higher bone resolution, multiplanar correction, lower radiation doses, faster scans, and lower cost. Depending on the individual, paranasal sinuses grow differently (1). Maxillary sinuses can even vary in a single person. Numerous events and injuries are effective on maxillary sinus size following rapid growth. Maxillary sinus development is directly related to the alveolar bone and palate. Anatomical characteristics of the skull and face can be affected by a significant change in maxillary sinus volume, because of its large volume. The maxillary sinus hypoplasia can additionally result in facial asymmetry (9).

Objectives

Accordingly, this study tends to determine the relationship between NSD and maxillary sinus volume using CBCT.

Materials and Methods

Study design

For the study, 257 samples were collected with all the information available in the archives of a private

maxillofacial radiology clinic in Ahvaz from October 2020 to June 2021 for analysis; of them, 47 samples were excluded due to the presence of sinusitis, lack of full coverage of maxillary sinus and crista galli in the images and incomplete information. Finally, this study involved 210 samples (420 maxillary sinuses) and CBCT images acquired in three different sections consists of axial, coronal, and sagittal. We obtained all images with the CBCT device (NewTom Giana, QR, Verona, Italy) with 11 × 13 FOV and saved in NNT Viewer (QR, Verona, Italy, version 10.1); these images are available in the archive. Images were taken with 90 KVP and exposure conditions depending on the selected voxel size and FOV.

Observations were performed in a semi-dark room using a 14-inch screen (LED flat screen, ASUS) with a resolution of 1920×10×1080. To calculate maxillary sinus volume, Medical mode of NNT Viewer (QR, Verona, Italy, version 10.1) was used and the desired range was determined. In order to evaluate CBCT scans of patients, images were exported in the form of DICOM images, and then imported into the NNT Viewer software (QR, Verona, Italy, version 10.1). All CBCT images were provided and analyzed by an observer.

Inclusion criteria included acceptable image quality, information on gender and age of the patient, age over 12 years and full coverage of maxillary sinus and nasal septum and crista galli area. Aside from artifacts in images, there were several exclusion criteria consisted of previous surgeries on the maxillary sinuses, pathologies of the maxillary sinus such as cysts and tumors, chronic and acute sinusitis, polyposis of the sinuses or nose, and abnormalities of the craniofacial structure, such as cleft lip and palate. To measure maxillary sinus volume, patient images were examined in axial, coronal and sagittal views. First, the area in the axial image was selected in a section where the maxillary sinus and nasal cavity were distinguished separately, and then corrections were made in other views (coronal, sagittal). For this purpose, we measured the sinus height from the sinus floor to the maxillary sinus roof using coronal view. The maxillary sinus width is determined by measuring the distance between its inner wall and its outermost point on the coronal images. Sagittal view also indicated the length of the anterior-posterior dimension of the sinus as the distance between the anterior and posterior points of the sinus. Similarly, both maxillary sinuses of each patient were evaluated. Finally, the maxillary sinus volume was compared on both sides (Figure 1).

To evaluate NSD, a line was drawn from the maxillary spine to the Crista galli and from the crista galli to the nasal septum with the greatest deviation. Then the angle between these two lines was considered as deviated nasal septum. Identifying the direction of deviation can be determined by the convex deviation. Cases without deviation were introduced as control group and cases with septum deviation consisted of 3 groups based on the

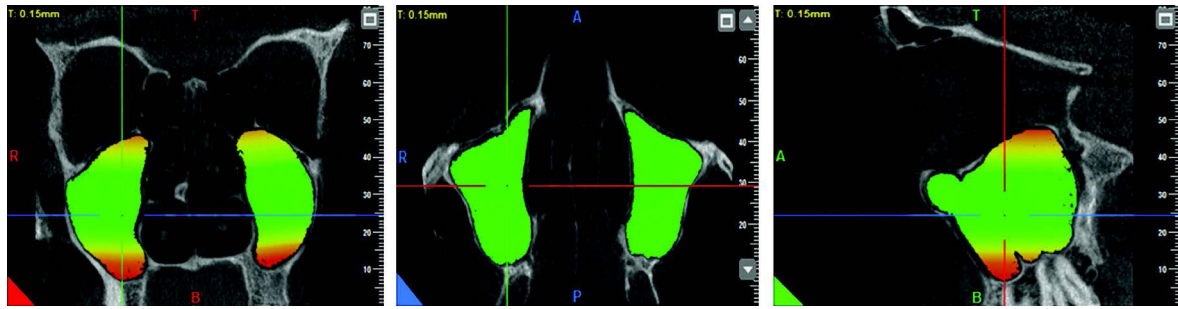


Figure 1. Measurement of maxillary sinus volume.

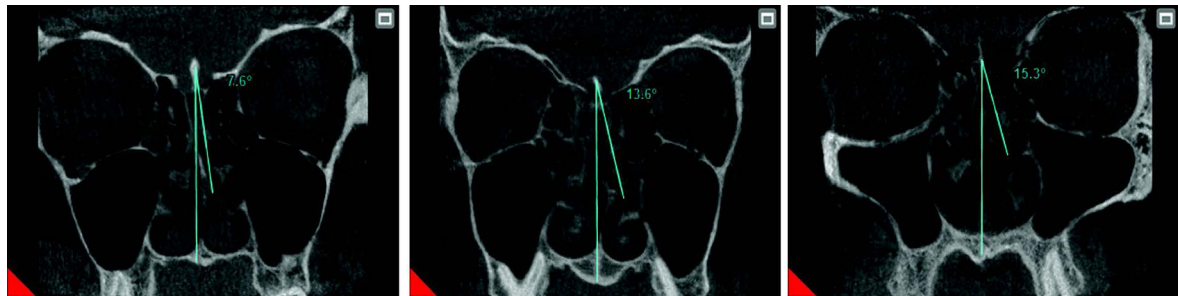


Figure 2. Measurement of nasal septum deviation.

degree of NSD, as Elahi et al noted (10); Group 1 included NSD less than 9 degrees, group 2 included NSD from 9-14 degrees, group 3 included NSD equal to greater than 15 grade (Figure 2).

Statistical analysis

An analysis of 210 maxillary CBCT images was conducted by census of all images held in the archives of a private maxillofacial radiology clinic in Ahvaz. NNT Viewer version 10.1 software was used to view the data ($P < 0.05$). SPSS (version 22) was used to analysis of variance and t test, Excel and GraphPad Prism (version 8.0.2) software.

Results

The statistical population included 210 people (420 cases of maxillary sinus) including 100 men (52.4%) and 110 women (47.6%). This study included male patients between the ages of 18-58 (28.73 ± 9.16) years old and among the female patients, the range of ages was 18-75 (30.61 ± 9.84) years old and the mean age of patients was 29.71 ± 9.55 years old. There was no significant difference between women and men in terms of age ($P > 0.05$). Regarding the descriptive statistics related to two sides of the maxillary sinus volume, as shown in Table 1, volume of the right maxillary sinus was 4.83 cm^3 at minimum and 19.73 cm^3 at maximum. Moreover, volume of the left maxillary sinus was 4.68 cm^3 at minimum and 21.20 cm^3 at maximum. As a result, maxillary sinus volume ranged from 4.68 cm^3 to 20.21 cm^3 . The maxillary sinus volumes were $13.04 \pm 3.37 \text{ cm}^3$ in the left and $13.59 \pm 3.33 \text{ cm}^3$ in the right.

In general, the mean sinus volume was $13.315 \pm 3.35 \text{ cm}^3$ and there was no significant difference between volumes

of the right and left maxillary sinuses ($P > 0.05$).

According to Table 2, there is a correlation between right maxillary sinus volume and gender. Mean volume of the right sinus was $14.45 \pm 3.32 \text{ cm}^3$ in men, whereas it was $11.75 \pm 2.88 \text{ cm}^3$ in women. Moreover, the mean volume of the left maxillary sinus was $14.75 \pm 3.20 \text{ cm}^3$ in men and $12.54 \pm 3.10 \text{ cm}^3$ in women; in general, the mean maxillary sinus volume was $14.60 \pm 5.10 \text{ cm}^3$ in men and $12.15 \pm 4.60 \text{ cm}^3$ in women. Men had considerably higher right and left maxillary sinus volumes than women, according to our findings ($P < 0.05$).

As shown in Table 3, there is a negative linear relationship between right, left, and total maxillary sinus volume (cm^3) and age, and generally maxillary sinus volume decreases

Table 1. An analysis of the volume of each maxillary sinus

	N	Minimum	Maximum	Mean
Right MS volume (cm^3)	210	4.83	19.73	13.04 ± 3.37
Left MS volume (cm^3)	210	4.68	21.20	13.59 ± 3.33
Total MS volume (cm^3)	420	4.68	21.20	13.315 ± 3.35

MS, maxillary sinus.

Table 2. Comparing the size of women's and men's maxillary sinuses

	Male (n=100) Mean \pm SD	Female (n=110) Mean \pm SD	P value
Right MS volume (cm^3)	14.45 ± 3.32	11.76 ± 2.88	< 0.05
Left MS volume (cm^3)	14.75 ± 3.20	12.54 ± 3.10	< 0.05
Total MS volume (cm^3)	14.60 ± 5.10	12.15 ± 4.60	< 0.05

MS, maxillary sinus.

* $P < 0.05$, Significant difference by student's t test.

Table 3. Investigation of the relationship between maxillary sinus volume and age

	Age	
	R	P value
Right MS volume (cm ³)	-0.281 ^a	<0.05
Left MS volume (cm ³)	-0.331 ^a	<0.05
Total MS volume (cm ³)	-0.379 ^a	<0.05

MS, maxillary sinus.

^b Pearson correlation coefficient.

* Correlation is significant at the 0.01 level (2-tailed).

with age.

Regarding the maxillary sinus volume based on NSD in general, the septum deviation ranged from 0 to 19.4 degrees (mean of NSD was 8.44 ± 4.85 degree angle). In our study, 22 patients without septum deviation were assigned to control group and the remaining groups included group 1 (mild, n = 80; 38.1%), group 2 (moderate, n = 79; 37.6%), and group 3 (severe, n = 29; 13.8). Regarding the frequency of septum deviation, right septum deviation was seen in 113 patients (53.8%) and left septum deviation was seen in 75 patients (35.7%) and no septum deviation was seen in 22 patients (10.5%). Analysis of the control group showed no significant difference in the mean volumes of the right and left maxillary sinuses (14.79 ± 1.90 cm³ and 14.93 ± 2.00 cm³, respectively; $P > 0.05$).

In contrast, the maxillary sinus volume significantly decreased on the same side as the deviated septum ($P < 0.001$), as shown in Table 4. Comparison of the maxillary sinus volume on both sides among patients in groups 1, 2 and 3 showed that the maxillary sinus volume was significantly smaller on the side of deviation than the opposite side in groups 2 and 3. However, there was no significant difference in group 1 (Table 5).

A difference was found in maxillary sinus volume on the opposite side of the deviated septum between the groups

Table 4. Maxillary sinuses volume based on direction of nasal septum deviation

	Deviation side	
	Right (n=113) Mean \pm SD	Left (n=75) Mean \pm SD
Right MS volume (cm ³)	11.80 \pm 3.20	14.40 \pm 3.23
Left MS volume (cm ³)	14.70 \pm 2.89	11.53 \pm 3.28
P value	<0.05	<0.05

MS, maxillary sinus.

* $P < 0.05$, significant difference by the paired samples *t* test.**Table 5.** Maxillary sinus volume based on nasal septum deviation in subgroups with deviated nasal septum

Side	Group 1 (n=80), Mean \pm SD	Group 2 (n=79), Mean \pm SD	Group 3 (n=29), Mean \pm SD
Deviation side volume (cm ³)	13.02 \pm 3.38	11.20 \pm 2.62	9.37 \pm 2.64
Contralateral side volume (cm ³)	13.26 \pm 3.35	15.47 \pm 2.40	15.83 \pm 2.15
P value	>0.05	<0.05	<0.05

* $P < 0.05$, Significant difference by student's *t* test.

with septum deviation. This difference was significant between the groups 1 and 2, the groups 1 and 3, as shown in Tables 6 and 7; the values of the groups 2 and 3 were significantly higher than group 1 ($P < 0.05$).

Comparison of the maxillary sinus volumes between the control group and the group 3 showed significant differences ($P < 0.05$); however, the left maxillary sinus volume was not significantly different between the groups ($P > 0.05$) (Table 8).

Discussion

The maxillary sinus is very important in the maxillofacial area because it is anatomically close to other structures and it has the largest volume between the paranasal sinuses. To maintain normal physiology, the paranasal sinuses need adequate ventilation. Any obstruction that affects the osteomeatal complex can alter the physiology of the sinuses (11). According to the findings of this study, we suggested that damage and situation of adjacent structures can change the size of the maxillary sinus volume. NSD-induced nasal obstruction can increase the resistance of the nasal airway and cause cramped nose, nose drought and scaling, recurrent nose bleeding, and recurrent sinusitis (4). Previous studies have measured the volume of paranasal sinuses on corpses, dry skulls and using computed tomography (CT), magnetic resonance imaging (MRI) and CBCT (1). These volume measurement techniques on dry corpses and skulls cannot be used in living subjects (12). In addition, a dry skull may have larger volume than its true size due to a lack of soft tissues (1).

The new 3D technology, CBCT, was first applied in 1982 to angiograms and later to maxillofacial imaging. For this reason, the present study used CBCT technology to measure maxillary sinus volume.

A period of rapid growth occurred in the maxillary sinus between birth and age 3 years old, and another between ages of 7 and 12 years old. The maxillary sinus grows approximately between the ages of 12 and 15 years old following these two rapid growth stages (1). Several study reported that maxillary sinus volume did not significantly increase after the age of 12 years old (13). Thus, this study tended to measure the maxillary sinus volume in adults older than 12 years of age.

According to this study, maxillary sinus volume has a negative correlation with age; thus, maxillary sinus volume decreases with age. This finding is in consistent with Kalabalık and Tarım Ertaş (1), Cho et al (9) and Cohen et

Table 6. The left maxillary sinus volume in patients with a right deviation of the nasal septum

Deviation angle	Group I (0°-9°)	Group II (9°-15°)	Group III (15°+)	Total	P value		
					I-II	I-III	II-III
N	47	46	20	113			
Mean volume	13.49±3.22 ^a	15.45±2.30 ^a	15.83±2.30 ^a	14.70±2.89 ^a	0.002*	0.005*	0.862

^a Mean ± SD.

*P < 0.05, significant difference by one-way analysis of variance (ANOVA).

Table 7. Right maxillary sinus volume in cases with deviation of the nasal septum to the left

Deviation angle	Group I (0°-9°)	Group II (9°-15°)	Group III (15°+)	Total	P value		
					I-II	I-III	II-III
N	33	33	9	75			
Mean volume	12.93±3.55 ^a	15.49±2.58 ^a	15.82±1.90 ^a	14.40±3.23 ^a	0.003*	0.033*	0.952

^a Mean ± SD.

*P < 0.05, significant difference by one-way analysis of variance (ANOVA).

Table 8. Comparison of maxillary sinus volumes in different groups

Deviation angle	Group I (0°-9°)	Group II (9°-15°)	Group III (15°+)	Group Control	Total
N	80	79	29	22	210
Right maxillary sinus volumes	13.07±3.31 ^a	13.11±3.31 ^a	11.46±3.96 ^a	14.79±1.90 ^a	13.04±3.37 ^a
Left maxillary sinus volumes	13.21±3.43 ^a	13.55±3.28 ^a	13.74±3.84 ^a	14.93±2.00 ^a	13.59±3.33 ^a

^a Mean ± SD.

al (14) and Ekizoglu et al (15).

Inconsistent to our study, a number of other studies, including Kim et al (16), Sahlstrand-Johnson et al (17) and Orhan et al (8) reported of no significant relationship between maxillary sinus volume and age in patients over 18 years of age. However, each study was conducted with less number of samples than 80 patients, which may explain why no correlation was found.

In addition, Karataş et al (19) examined the effect of NSD on volume of the frontal and maxillary sinuses, and studies carried out on patients aged 5-55 indicate that the paranasal sinuses become larger with age.

However, as noted, maxillary sinus has two growth peaks; hence, this positive correlation may be attributed to inclusion of very young patients (younger than 12 years) and fewer number of cases studied (19).

In the present study, male patients had significantly higher volumes of right, left, and total maxillary sinuses than female patients. In general, men are larger than women, which may account for the difference in maxillary sinus volume between men and women. This finding was consistent with Kalabalık and Tarım Ertaş (1) and Cohen et al (14). However, Saccucci et al (20) found no statistical difference in the maxillary sinus volume of patients based on gender.

In the present study, moderate or severe NSD significantly decreased the maxillary sinus volume, while mild deviations had no effect, which is in accordance with the study by Kalabalık and Tarım Ertaş (1).

In our study, a comparison was made between subgroups with septum deviation in terms of maxillary sinus volume

on the opposite side of NSD. We consequently found a significant differences between groups 1 and 2, as well as between groups 1 and 3. Likewise, Karataş et al found a significant difference between groups 2 and 3 and between groups 1 and 2. Due to small numbers of samples and different numbers in different subgroups in these studies, this could be the reason for the difference (19).

According to our study, NSDs, either mild or severe, inhibit maxillary sinus growth on the side of the deviation. If growth is insufficient on the deviation side of the maxillary sinus, it is likely due to inadequate ventilation. We recommend controlling nasal breathing in dental patients, particularly adolescents. An ear, nose, and throat (ENT) specialist should be consulted if nasal breathing is impaired. Thus, treating conditions such as NSD, which may lead to nasal breathing disorders, may prevent cranial and facial disorder. In addition, considering the greater accuracy of the image, dentists are recommended to use CBCTs in order to assess NSD. When diagnosing moderate to severe NSD by CBCT imaging, patients are recommended to visit an ENT specialist for further evaluation.

Conclusion

According to our study, severe and moderate deviations of the nasal septum prevent sufficient development of the maxillary sinuses on the same side of the deviation. Additionally, the average volume of the maxillary sinus on both sides is greater in men than women while a negative relationship between age and the maxillary sinus volume was detected.

Limitations of the study

Due to the uncommonness of individuals without any deviation of the nasal septum, the collection of samples from the control group was limited. Besides, due to the time constraints of this study, it was not possible to follow patients and examine sinus disorders in the future, which is suggested to be considered in future research.

Authors' contribution

Conceptualization: MR.

Methodology: MR.

Validation: MR and NS.

Formal analysis: SMAP.

Investigation: SMAP.

Resources: SMAP.

Data curation: MR and SMAP.

Original draft preparation: SMAP.

Review and editing: MR and NS.

Visualization: MR and SMAP.

Supervision: MR and NS.

Project administration: MR.

Funding acquisition: MR and SMAP.

Conflicts of interest

The authors declare that they have no conflicts of interest.

Ethical issues

The research followed the tenets of the Declaration of Helsinki. The Ethics Committee of Ahvaz Jundishapur University of Medical Sciences approved this study (ethical code #IR.AJUMS.REC.1400.167). Accordingly, written informed consent was taken from all participants before any intervention. This study was extracted from a thesis by Seyed Mohammad Ali Pirasteh at this university (Thesis #330098869). Besides, ethical issues (including plagiarism, data fabrication and double publication) have been completely observed by the authors.

Funding/Support

This work was financially supported by Vice Chancellor for Research Affairs of Ahvaz Jundishapur University of Medical Sciences (project number: of U-00099).

References

- Kalabalik F, Tarım Ertaş E. Investigation of maxillary sinus volume relationships with nasal septal deviation, concha bullosa, and impacted or missing teeth using cone-beam computed tomography. *Oral Radiol.* 2019;35:287-295. doi: 10.1007/s11282-018-0360-x.
- Yamaguchi K, Munakata M, Kataoka Y, Uesugi T, Shimoo Y. Effects of missing teeth and nasal septal deviation on maxillary sinus volume: a pilot study. *Int J Implant Dent.* 2022;8:19. doi: 10.1186/s40729-022-00415-5.
- Jadia S, Qureshi S, Agrawal S, Singh SG. Effect of Deviated Nasal Septum on Maxillary Sinus Volume and Occurrence of Sinusitis. *Indian J Otolaryngol Head Neck Surg.* 2019;71:1871-5. doi: 10.1007/s12070-018-1276-9.
- Aziz T, Biron VL, Ansari K, Flores-Mir C. Measurement tools for the diagnosis of nasal septal deviation: a systematic review. *J Otolaryngol Head Neck Surg.* 2014;43:11. doi: 10.1186/1916-0216-43-11.
- D'Ascanio L, Lancione C, Pompa G, Rebuffini E, Mansi N, Manzini M. Craniofacial growth in children with nasal septum deviation: a cephalometric comparative study. *Int J Pediatr Otorhinolaryngol.* 2010;74:1180-3. doi: 10.1016/j.ijporl.2010.07.010.
- Kapusuz Gencer Z, Özkırış M, Okur A, Karaçavuş S, Saydam L. The effect of nasal septal deviation on maxillary sinus volumes and development of maxillary sinusitis. *Eur Arch Otorhinolaryngol.* 2013;270:3069-73. doi: 10.1007/s00405-013-2435-y.
- Schubert MS. A superantigen hypothesis for the pathogenesis of chronic hypertrophic rhinosinusitis, allergic fungal sinusitis, and related disorders. *Ann Allergy Asthma Immunol.* 2001;87:181-8. doi: 10.1016/S1081-1206(10)62222-3.
- Orhan I, Ormeci T, Aydin S, Altin G, Urger E, Soylu E, et al. Morphometric analysis of the maxillary sinus in patients with nasal septum deviation. *Eur Arch Otorhinolaryngol.* 2014;271:727-32. doi: 10.1007/s00405-013-2617-7.
- Cho SH, Kim TH, Kim KR, Lee JM, Lee DK, Kim JH, et al. Factors for maxillary sinus volume and craniofacial anatomical features in adults with chronic rhinosinusitis. *Arch Otolaryngol Head Neck Surg.* 2010;136:610-5. doi: 10.1001/archoto.2010.75.
- Elahi MM, Frenkiel S, Fageeh N. Paraseptal structural changes and chronic sinus disease in relation to the deviated septum. *J Otolaryngol.* 1997;26:236-40.
- Tassoker M, Magat G, Lale B, Gulec M, Ozcan S, Orhan K. Is the maxillary sinus volume affected by concha bullosa, nasal septal deviation, and impacted teeth? A CBCT study. *Eur Arch Otorhinolaryngol.* 2020;277:227-233. doi: 10.1007/s00405-019-05651-x.
- Kim J, Kim SW, Kim SW, Cho JH, Park YJ. Role of the sphenoidal process of the septal cartilage in the development of septal deviation. *Otolaryngol Head Neck Surg.* 2012;146:151-5. doi: 10.1177/0194599811425000.
- Bhushan B, Rychlik K, Schroeder JW Jr. Development of the maxillary sinus in infants and children. *Int J Pediatr Otorhinolaryngol.* 2016;91:146-151. doi: 10.1016/j.ijporl.2016.10.022.
- Cohen O, Warman M, Fried M, Shoffel-Havakuk H, Adi M, Halperin D, et al. Volumetric analysis of the maxillary, sphenoid and frontal sinuses: A comparative computerized tomography based study. *Auris Nasus Larynx.* 2018;45:96-102. doi: 10.1016/j.anl.2017.03.003.
- Ekizoglu O, Inci E, Hocaoglu E, Sayin I, Kayhan FT, Can IO. The use of maxillary sinus dimensions in gender determination: a thin-slice multidetector computed tomography assisted morphometric study. *J Craniofac Surg.* 2014;25:957-60. doi: 10.1097/SCS.0000000000000734
- Kim J, Song SW, Cho JH, Chang KH, Jun BC. Comparative study of the pneumatization of the mastoid air cells and paranasal sinuses using three-dimensional reconstruction of computed tomography scans. *Surg Radiol Anat.* 2010;32:593-9. doi: 10.1007/s00276-009-0618-4.
- Sahlstrand-Johnson P, Jannert M, Strömbeck A, Abul-Kasim K. Computed tomography measurements of different dimensions of maxillary and frontal sinuses. *BMC Med Imaging.* 2011;11:8. doi: 10.1186/1471-2342-11-8.
- Emirzeoglu M, Sahin B, Bilgic S, Celebi M, Uzun A. Volumetric evaluation of the paranasal sinuses in normal subjects using computer tomography images: a stereological study. *Auris Nasus Larynx.* 2007;34:191-5. doi: 10.1016/j.anl.2006.09.003.
- Karataş D, Koç A, Yüksel F, Doğan M, Bayram A, Cihan MC. The Effect of Nasal Septal Deviation on Frontal and Maxillary Sinus Volumes and Development of Sinusitis. *J Craniofac Surg.* 2015;26:1508-12. doi: 10.1097/SCS.0000000000001809.
- Saccucci M, Cipriani F, Carderi S, Di Carlo G, D'Attilio M, Rodolfo D, et al. Gender assessment through three-dimensional analysis of maxillary sinuses by means of cone beam computed tomography. *Eur Rev Med Pharmacol Sci.* 2015;19:185-93.