



Maxillary sinus metastasis in breast cancer; a case report and review of the literature

Maryam Ghazizadeh¹, Matin Ghazizadeh^{2*}

¹Department of Hematology-Oncology, Shahid Modarres Hospital, Shahid Beheshti University of Medical Sciences, Tehran, Iran

²Head and Neck Surgery, Department of Otolaryngology, Head and Neck Surgery, Taleghani Hospital, Shahid Beheshti University of Medical Sciences, Tehran, Iran

*Correspondence to

Matin Ghazizadeh, Email:
matinghazizadeh@hotmail.com,
matinghazizadeh@sbmu.ac.ir

Received 8 Aug. 2020

Accepted 20 Oct. 2020

Published online 9 Nov. 2020

Keywords: Breast cancer, Metastasis, Paranasal sinuses

Abstract

Paranasal sinuses are an infrequent site for tumor metastasis, and breast cancer metastasis to these sinuses is very rare. To date, less than 20 cases of breast cancer metastasis to paranasal sinuses have been reported. This case study's purpose was to describe a 69-year-old woman with a history of breast cancer treated 15 years ago who developed the symptoms of rhinosinusitis. Physical examination showed exophthalmos and maxillary sinus tenderness. Finally, breast cancer metastasis to paranasal sinuses was diagnosed using CT scan. She received hormone therapy, systemic chemotherapy, and maxillary sinus radiotherapy. The treatment was well tolerated, and lesions observed in CT scan improved and after more than a year the patient is still alive.

Citation: Ghazizadeh M, Ghazizadeh M. Maxillary sinus metastasis in breast cancer; a case report and review of the literature. *Immunopathol Persa*. 2024;10(1):e16212. DOI:10.34172/ipp.2022.16212.

Introduction

Bones are the most common site for breast cancer metastasis and they are involved in 70% of cases of metastatic breast cancer (1). Moreover, ribs, spine, pelvis, and long bones in arms and legs are the most common sites affected by bone metastasis in patients with breast cancer. On the other hand, tumors leading to metastasis to paranasal sinuses and nose are mainly observed in renal cancer (2), followed by testicular tumor, bronchial cancer, and gastrointestinal cancer (3). Breast cancer metastasis to nose and paranasal sinuses is rare (4). However, it can lead to the metastasis to other sites of facial maxillary, including the sphenoid sinus (5,6). Metastatic cancers to paranasal sinuses can be asymptomatic, characterized by facial pain, epistaxis, nasal obstruction, and facial asymmetry, or may emerge as primary facial cancer. In addition, tumor cells can spread through blood vessels to the central nervous system, causing metastasis at the base of the skull through paranasal sinuses (7).

In this study, we present a case of breast cancer leading to metastasis to maxillary sinus, zygomatic bone, sphenoid and temporal bone, and skull base 15 years after the treatment of the primary tumor. The patient underwent hormone therapy, chemotherapy, and radiotherapy of maxillary sinus and finally, the

Key point

In each patient with history of breast cancer who presents with symptoms of rhinosinusitis, metastasis to paranasal sinuses should be considered.

metastatic tumor regressed.

Case Presentation

In 2004, a 69-year-old woman was diagnosed with T2N1M0 invasive ductal carcinoma of the right breast. Estrogen and progesterone receptor was positive, Ki67 was 60%, and human epidermal growth factor receptor (HER2) was negative. Primary cancer was treated via mastectomy and lymph node dissection. The woman received adjuvant anthracycline-based chemotherapy (4 cycles of doxorubicin and cyclophosphamide), followed by 4 cycles of paclitaxel. She received adjuvant breast radiotherapy (50 Gy to the whole breast plus 16 Gy on tumor bed). Then, she was treated using an aromatase inhibitor (letrozole 2.5 mg/daily) for 5 years.

In July 2019, she presented the signs of sinusitis-like rhinorrhea, headache, post-nasal discharge, and nasal obstruction. In physical examination, right exophthalmos and right maxillary sinus tenderness were detected. Therefore, the patient underwent a CT scan of the paranasal sinuses that



showed soft tissue density in the maxilla in the right maxillary sinus. In addition, a mixed lytic sclerotic bone destructive lesion was observed in right zygomatic bone, right wings of sphenoid bone, and right temporal bone with peripheral soft tissue component extension of dura arachnoid of the brain in favor of metastasis (Figures 1 and 2). Abdominopelvic CT scan was normal. Chest CT scan showed heterogeneous sclerosis in lateral arch of the right fifth rib due to blastic bone metastasis. The mosaic pattern in both lungs field, and air trapping and distal airway disease were also observed.

A biopsy was collected from the right maxillary sinus and right maxillary bone lesion, and the results of tests confirmed invasive carcinoma with a mucinous feature. The subsequent immunohistochemical analysis confirmed the metastatic form of breast cancer with a positive profile of estrogen receptor, negative progesterone receptor, negative HER2, positive cytokeratin 7 (CK7), and negative caudal type homeobox transcription factor-2 (CDX2). Thus, sinusoidal breast metastasis was reported as the final diagnosis.

In order to control bone metastasis, the patient was treated using mTOR inhibitor (everolimus) and aromatase inhibitor exemestane with monthly zoledronic acid. The treatment was well-tolerated, but the patient complained of mucosal ulcers. Three months later, the patient underwent a CT scan re-evaluation that showed stable disease in right maxillary sinus, right zygomatic, sphenoid bone, and soft tissue component. Because of the extension of the tumor to the dura arachnoid and skull base, she received intensity-modulated radiotherapy (IMRT) (60 Gy full dose in 12 fractions) of facial bone to eradicate tumor and reduce the risk of recurrence. The treatment was well tolerated and three weeks after IMRT, she received six courses of nab-paclitaxel. At the end of the chemotherapy, a CT scan revealed stable disease in the bone and a reduction in the size of the soft tissue component. Finally, she received exemestane for three months. Now, she is still receiving exemestane and monthly zoledronic acid. Stable disease has been observed in CT scans since a year ago. Figure 3 shows the post-treatment MRI with the remnant of maxillary and temporal lesions.

Discussion

Bone, lung, liver, and brain are the most common sites for the emergence of breast cancer metastasis (8). The involvement of paranasal sinuses in breast cancer is infrequent and breast cancer metastasis to paranasal sinuses has been reported in less than 20 patients (9). The most usual site of breast cancer metastasis to paranasal sinuses is maxillary sinus and maxillary antrum (2,6), followed by ethmoid, frontal, and sphenoid sinuses, respectively. Metastasis can occur via hematogenous or lymphatic vessels. It seems that the most likely routes for breast metastasis to paranasal sinuses are hematogenous via vena-cava, pulmonary circulation, and arterial

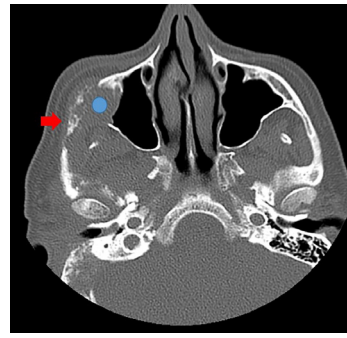

Figure 1. Axial pre-treatment paranasal sinus CT scan without contrast at zygomatic arch level. The red arrow shows an osteolytic metastatic lesion in the right zygomatic arch and the blue circle shows a metastatic mass lesion in the right maxillary sinus with osteolytic involvement of the posterolateral wall.

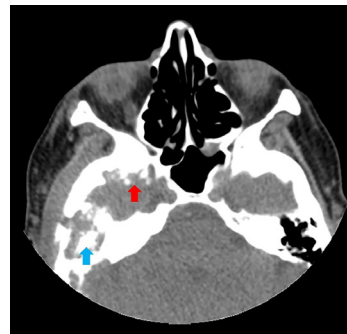


Figure 2. Axial pre-treatment paranasal sinus CT scan without contrast at sphenoid sinus level. The red arrow shows an osteolytic metastatic lesion in the right greater wing of the sphenoid sinus, and the blue arrow shows an osteolytic metastatic lesion in the right temporal bone.

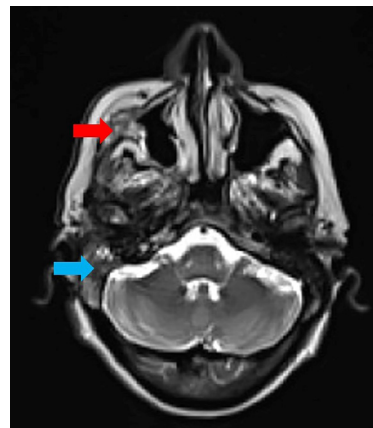


Figure 3. Post-chemotherapy MRI. The red arrow shows the remnant of a maxillary lesion, and the blue arrow shows the remnant of a temporal lesion.

supply of head and neck (10). The spread of metastasis through venous Batson route along with prevertebral venous plexus is also reported (7). In addition, breast metastases to larynx, nasopharynx, parotid gland, and nose have also been reported. Metastases of skull base can be synchronous with paranasal sinuses. According to a report, the incidence of HER2 positive receptors is higher in breast cancer metastasis to paranasal sinus, but based on

another study, its incidence is only 36%. Estrogen receptor and progesterone receptor reported positive in 71% of patients with paranasal sinus metastasis (11). The interval between the diagnosis of breast cancer and paranasal sinus metastasis is reported from three months to 12 years. Although acute invasive fungal sinusitis is common in immune-compromised patients and those with hematologic malignancy (12), the common symptoms of breast cancer metastasis to paranasal are similar to those of rhinosinusitis. Therefore, these symptoms lead to a delay in diagnosis.

The differential diagnosis of breast cancer metastasis to paranasal sinus includes benign tumors, inflammatory lesions, lymphoproliferative diseases, Wegener's granulomatosis, malignant tumor-like sinus plasmacytoma, and sarcoidosis (13). The finding of CT scan of paranasal sinus lesion can somewhat help distinguish between benign and malignant lesions. Bone erosion or destruction and angiogenesis or invasion of the sphenopalatine of the foramen are the signs of malignancy. MRI is superior to CT scan for determining disease extension to skull base or leptomeningeal involvement. In addition, a diagnostic biopsy is recommended for confirming the diagnosis.

To improve symptoms and signs, radiation and chemotherapy are the appropriate treatment for breast cancer metastasis to paranasal sinuses. Surgical resection is not recommended and is reserved for palliative treatment of cases with uncontrolled local symptoms. Hormone therapy is also recommended as a palliative therapy for cases with estrogen or progesterone receptor positive breast cancer (14). Despite the presence of the mentioned treatment options, the prognosis in these patients is very poor and the median survival is from 22 to 31 months (7).

In our case, rhinorrhea, headache, post-nasal discharge, and nasal obstruction were the observed clinical symptom. The clinical symptoms observed in our case were not different from those observed in other cases with breast cancer metastasis to paranasal sinuses, but our case was HER2 negative, unlike the cases reported by Pittoni et al, that was HER2 positive (7). Similar to 71% of other patients with breast cancer metastasis to paranasal sinuses, estrogen and progesterone receptor was positive in our cases. Paranasal sinus metastasis in our case occurred 15 years after the diagnosis of primary tumors, though in the other reports, the longest time between the diagnosis of the primary tumor and the occurrence of paranasal sinus metastasis was 12 years. Our case had lesions in right maxillary sinus and bone that are the most common sites for breast cancer metastasis to paranasal sinus, like other reports. In our case, bone lesions became stable via hormone therapy with mTOR inhibitor, but soft tissue metastasis decreased in size only after radiotherapy and chemotherapy.

The reported median survival of patients with breast cancer metastasis to paranasal sinus is 22 to 31 months (7).

Our patient is alive and stable since a year ago. Although breast cancer metastasis to paranasal sinus has a poor prognosis, palliative chemotherapy and radiotherapy could increase the length of survival. Therefore, to achieve the best results, proper interaction between the surgeon and the oncologist is essential.

Conclusion

Paranasal sinus metastasis is a rare presentation of breast cancer that could occur months to years after the treatment of primary tumor. Its clinical symptoms are similar to those of rhinosinusitis. Therefore, physicians should be suspicious of diagnosis in patients with a history of breast cancer and signs of sinusitis or nasal obstruction, and bone erosion or destruction observed in CT scan. Although its prognosis is poor, palliative chemotherapy and radiotherapy are recommended under such a situation.

Authors' contribution

Conceptualization: Maryam Ghazizadeh, Matin Ghazizadeh.

Data curation: Maryam Ghazizadeh, Matin Ghazizadeh.

Formal analysis: Maryam Ghazizadeh, Matin Ghazizadeh.

Investigation: Matin Ghazizadeh.

Project administration: Matin Ghazizadeh.

Resources: Maryam Ghazizadeh, Matin Ghazizadeh.

Supervision: Maryam Ghazizadeh, Matin Ghazizadeh.

Validation: Maryam Ghazizadeh, Matin Ghazizadeh.

Visualization: Maryam Ghazizadeh, Matin Ghazizadeh.

Writing—original draft: Maryam Ghazizadeh, Matin Ghazizadeh.

Writing—review & editing: Maryam Ghazizadeh, Matin Ghazizadeh.

Conflicts of interest

The authors declare that they have no competing interests.

Ethical considerations

Ethical issues including plagiarism, double publication, and redundancy have been completely observed by the authors. The patients gave her informed consent for the publication of this report and any identifying images.

Funding/Support

There is no funding support.

References

- Manders K, van de Poll-Franse LV, Creemers GJ, Vreugdenhil G, van der Sangen MJ, Nieuwenhuijzen GA, et al. Clinical management of women with metastatic breast cancer: a descriptive study according to age group. *BMC Cancer* 2006;6:179. doi:10.1186/1471-2407-6-179
- Bernstein JM, Montgomery WW, Balogh K. Metastatic tumors to the maxilla, nose, and paranasal sinuses. *Laryngoscope* 1966;76:621-50. doi: 10.1288/00005537-196604000-00003.
- Marchioni D, Monzani D, Rossi G, Rivasi F, Presutti L. Breast carcinoma metastases in paranasal sinuses, a rare occurrence mimicking a primary nasal malignancy. case report. *Acta Otorhinolaryngol Ital.* 2004;24:87-91.
- Friedmann I, Osborn DA. Metastatic tumours in the ear, nose and throat region. *J Laryngol Otol* 1965;79:576-91. doi:10.1017/s0022215100064100
- Jortay AM. Metastatic tumors in oral cavity pharynx and paranasal sinuses. *Acta Chir Belg* 1971;70:715-28.
- Austin JR, Kershiznek MM, McGill D, Austin SG. Breast

- carcinoma metastatic to paranasal sinuses. *Head Neck*. 1995;17:161-65. doi: 10.1002/hed.2880170217.
7. Pittoni P, Di Lascio S, Conti-Beltraminelli M, Valli MC, Espeli V, Bongiovanni M, et al. Paranasal sinus metastasis of breast cancer. *BMJ Case Rep*. 2014;2014:205171. doi:10.1136/bcr-2014-205171
 8. Carty NJ, Foggitt A, Hamilton CR, Royle GT, Taylor I. Patterns of clinical metastasis in breast cancer: an analysis of 100 patients. *Eur J Surg Oncol*. 1995;21:607-8. doi: 10.1016/s0748-7983(95)95176-8.
 9. Johnston J, George M, Karkos PD, Dwivedi RC, Leong SC. Late metastasis to macroscopically normal paranasal sinuses from breast cancer. *Ecancelmedicalscience*. 2013;7:298. doi: 10.3332/ecancer.2013.298.
 10. Nahum AM, Bailey BJ. Malignant tumors metastatic to the paranasal sinuses: case report and review of the literature. *Laryngoscope* 1963;73:942-53. doi: 10.1288/00005537-196307000-00009.
 11. Reitsma S, Schuil PJ. Metastasis of breast carcinoma to the paranasal sinus: report of two cases and systematic review of literature. *Rhinology Online* 2018;1:3-8. doi: 10.4193/RHINOL/18.001.
 12. Craig JR. Updates in management of acute invasive fungal rhinosinuitis. *Curr Opin Otolaryngol Head Neck Surg* 2019;27:29-36. doi: 10.1097/moo.0000000000000507.
 13. González F, López-Couto C. Orbital metastases. A report of four cases and a review of the literature. *Arch Soc Esp Oftalmol* 2006;81:451-62. doi:10.4321/s0365-66912006000800006.
 14. Weng B, Wang Q, Lin S, Lu Y. Nasal cavity metastasis of breast cancer: a case report and review of the literature. *Int J Clin Exp Pathol* 2014;7:7028-33.