



# Adhesive capsulitis; evaluation of a recently introduced MRI criterion

Samin Khoei<sup>1</sup>, Mahrooz Malek<sup>1</sup>, Mohaddeseh Azadvari<sup>2</sup>, Nima Bagheri<sup>3</sup>

<sup>1</sup>Department of Radiology, Imam Khomeini Hospital Complex, Tehran University of Medical Sciences, Tehran, Iran

<sup>2</sup>Department of Physical Medicine and Rehabilitation, Imam Khomeini Hospital Complex, Tehran University of Medical Sciences, Tehran, Iran

<sup>3</sup>Joint Reconstruction Research Center, Tehran University of Medical Sciences, Tehran, Iran

## \*Correspondence to

Mahrooz Malek, Email; mmalek@tums.ac.ir

Received 19 June 2022

Accepted 22 Aug. 2022

Published online 30 Aug. 2022

**Keywords:** Adhesive capsulitis; anterior capsular thickness; Magnetic resonance imaging

## Abstract

**Introduction:** Adhesive capsulitis is a common disorder, defined as the painful limitation of glenohumeral range of motion due to capsular hyperplasia and fibrosis. Magnetic resonance imaging (MRI) – as the gold standard of shoulder imaging- plays a critical role in diagnosis of adhesive capsulitis, in the early stages. The anterior predominance of pathologic and arthroscopic abnormalities suggest that the thickness of anterior joint capsule may be a more reliable diagnostic criterion on MRI; however, to our knowledge, only one study has evaluated the significance of this parameter up to now, the results of which, may be subject to substantial bias, due to small sample size.

**Objectives:** To evaluate the anterior capsule of glenohumeral joint, in terms of thickness and signal intensity, and also to conduct a comparison between adhesive capsulitis subjects and control individuals.

**Materials and Methods:** This is a case-control study. Cases were all patients with the final diagnosis of adhesive capsulitis, based on history, physical examination and imaging. Controls were all patients who underwent shoulder MRI, because of another reason. Anterior capsular thickness, and other qualitative and quantitative criteria were evaluated on the MRIs, by two musculoskeletal radiologists, with three and 10 years experience respectively.

**Results:** All of the evaluated criteria showed significant difference, between cases and controls. Considering the cut-off point equal to 1.3 mm, “anterior capsular thickness” had 86.7% sensitivity, 96.7% specificity, 96.3% positive and 87.9% negative predictive values respectively, which posed an acceptable position among MRI criteria of adhesive capsulitis. Of note, was the near perfect inter-observer agreement of this criterion between the two radiologists, implicating its practicality.

**Conclusion:** The anterior capsule signal and thickness are valuable criteria for diagnosis of adhesive capsulitis on MRI. Future studies with large sample volumes, clinical sub-categorization of the patients and multivariate analysis are recommended to more accurately define its role in MRI-based diagnosis of adhesive capsulitis.

**Citation:** Khoei S, Malek M, Azadvari M, Bagheri N. Adhesive capsulitis; evaluation of a recently introduced MRI criterion. Immunopathol Persa. 2022;x(x):e34438. DOI:10.34172/ipp.2022.34438.

## Introduction

Adhesive capsulitis is a common disorder, defined as the painful limitation of glenohumeral range of motion due to capsular hyperplasia and fibrosis (1). The disorder affects almost all aspects of a man's daily life, resulting in severe pain, anxiety, disability and sleep disorder (2). The symptoms usually persist for two years, however, a lifelong limited range of motion exist in 10% of the cases (1). The clinical course of the disease is divided into four stages: (a) First three months from onset of symptoms, (b) Three to nine months from onset, (c) Nine to fifteen months from onset and (d) 15 to 24 months from onset (3,4). Early-stage diagnosis results in effective conservative treatment- which in turn- reduces the duration of symptoms and patient's morbidity (5,6). The diagnostic criteria of adhesive capsulitis are entirely

## Key point

Adhesive capsulitis is a common disorder, defined as the painful limitation of glenohumeral range of motion due to capsular hyperplasia and fibrosis. Clinical criteria for diagnosis of adhesive capsulitis are quite variable and challenging. Different MRI criteria are suggested for the diagnosis up to date, one of which is the anterior capsule thickness. Anterior capsule thickness showed the highest diagnostic performance among other variables.

clinical, and include (a) More than 30 degrees limitation in glenohumeral range of motion (in comparison to the contralateral normal shoulder) in at least two planes, and (b) Gradually increasing shoulder pain for at least one month, which exacerbates at rest (7). The abovementioned criteria, however, are mild and variable in the first stages, making the diagnosis challenging; as a result



we could say no definitive criteria exist for the diagnosis of adhesive capsulitis to date (8). As a consequence magnetic resonance imaging (MRI) – as the gold standard of shoulder imaging- plays a critical role in diagnosis of adhesive capsulitis, in the early stages (9). Studies on histological aspects of adhesive capsulitis suggest the predominance of abnormalities in the anterior joint capsule, which include accumulation of myofibroblasts and collagenous matrix, focal fibrosis, inflammatory cytokines, regenerative neural fibers and increased vascularity in this region, which is interestingly absent in the inferior portion (2). Arthroscopic studies confirm the predominance of capsular thickening in its anterior aspect (7). The anterior predominance of pathologic and arthroscopic abnormalities suggest that the thickness of anterior joint capsule may be a more reliable diagnostic criterion on MRI; however, to our knowledge, only one study has evaluated the significance of this parameter; since, the results of which, may be subject to substantial bias, due to small sample size (7).

### Objectives

In the present study, we aimed to evaluate the significance of anterior capsular thickness in diagnosis of adhesive capsulitis on MRI.

### Materials and Methods

#### Study design

This study was an observational and case-control. Sampling was started upon approval of the study, by the biomedical research ethics committee, Tehran university of medical sciences, Tehran, Iran, on January the 22<sup>nd</sup> 2022. Diagnosis of adhesive capsulitis in our institution follows a clinical-radiologic approach. First impression is made based on clinical history and physical examination (which is performed by one orthopedics surgeon and one medical physicist). The clinical criteria include gradually progressing shoulder pain for a minimum period of one month, and more than 30-degree limitation of range of motion at two orthogonal planes in comparison with the contra-lateral normal shoulder. The patient is then referred for shoulder MRI, in order to rule out other possible differential diagnoses; if so, adhesive capsulitis becomes the final diagnosis, based on which the treatment begins. Arthroscopy is reserved for equivocal cases. Once the final diagnosis is made, our musculoskeletal radiologist saves the patient's MRI series on the Picture Archiving and Communication System (PACS, INFINITT Healthcare Co., Seoul, South Korea), inside a specific folder, named "Adhesive capsulitis". All the thirty recorded cases from January the 21<sup>st</sup> 2020 until January the 21<sup>st</sup> 2022 were selected as the adhesive capsulitis group.

Same number of patients, who were referred for shoulder MRI, for another reason (including shoulder mass, shoulder bony lesions and non-adhesive shoulder pain), in the same period of time, were collected randomly,

as the control group.

All cases and controls had undergone the same non-contrast-MRI protocol as follows;

The patient was supine, with his shoulder in maximum possible external rotation. The following sequences were obtained, by the same magnetic resonance scanner (Discovery™ MR750 3.0T, 60 cm MRI Scanner, GE Healthcare):

- 1- Oblique sagittal fat-suppressed proton density propeller sequence (TR/TE: 2487/49; section thickness 3.5 mm; matrix 256×256; FOV 160×160 mm)
- 2- Oblique coronal T2-weighted propeller imaging (TR/TE 5574/82; section thickness 3 mm; matrix 256×256; FOV 160×160 mm)
- 3- Oblique coronal fat-suppressed PD propeller imaging (TR/TE 2111/49; section thickness 3 mm; matrix 256×256; FOV 160×160 mm)
- 4- Oblique sagittal T1-weighted imaging (TR/TE 807/; section thickness 3.5 mm; matrix 288×256; FOV 160×160 mm)
- 5- Axial fat-suppressed PD propeller imaging (TR/TE 2999/41; section thickness 3.5 mm; matrix 256×256; FOV 160×160 mm)

Based on the sample volume formula for comparing two means, the minimum required sample volume was calculated as seven.

$$n = \frac{S_1^2 + S_2^2}{(M_1 - M_2)^2} * (Z_{1-\frac{\alpha}{2}} + Z_{1-\beta})^2$$

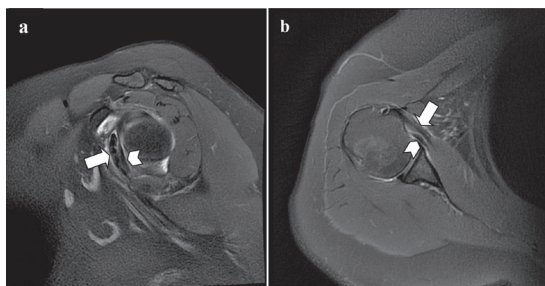
$$= \frac{1.64^2 + 0.79^2}{(3.99 - 1.66)^2} * (1.96 + 1.28)^2 = 7$$

Where S1, S2, M1 and M2 were derived from the previous similar study by Park et al (7), and the confidence interval and power were assumed as 95% and 90% respectively.

MRI variables of interest were measured independently, by two blinded radiologists, with 3 and 10 years experience in musculoskeletal imaging, respectively. After calculation of the inter-observer agreement, the radiologists studied the images for the second time, to reach a consensus on the results. The latter data was conducted for the rest of the statistical analysis.

The following quantitative variables were measured in the images;

- Anterior capsular thickness, defined as the thickest part of the glenohumeral capsule, at 2-5 o'clock, under the subscapularis tendon, which contains the middle and spiral glenohumeral ligaments, measured on oblique sagittal and axial proton-density weighted (PDW) images (Figure 1).
- Axillary recess capsular thickness, defined as the maximum capsular thickness in the 6 o'clock, measured on oblique coronal PDW images (Figure 2a).
- Glenoid capsular thickness in the axillary recess, defined as the maximum thickness of the glenoid

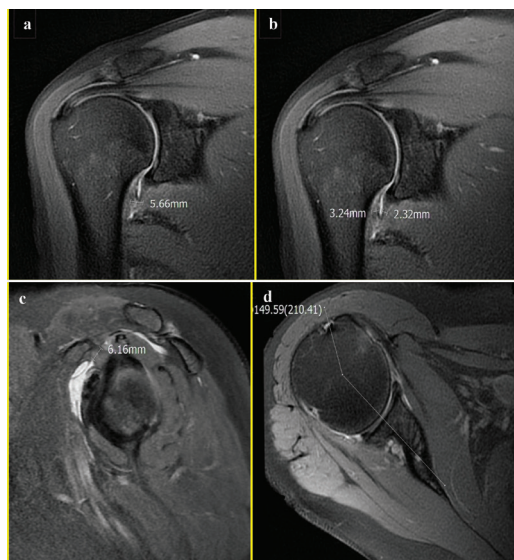


**Figure 1.** Sagittal (a) and axial (b) proton-density weighted MRI of a 56-year-old female in the adhesive capsulitis group, showing the anterior capsule of the glenohumeral joint (arrowhead), coursing beneath the subscapularis tendon (arrow), with normal signal and thickness.

side of axillary recess capsule, measured on oblique coronal PDW images (Figure 2b).

- Humeral capsular thickness in the axillary recess, defined as the maximum thickness of the humeral side of axillary recess capsule, measured on oblique coronal PDW images (Figure 2b).
- Coracohumeral ligament thickness, defined as the thickest part of the ligament measured on the oblique sagittal PDW images (Figure 2c).
- Maximum degree of external rotation, defined as the angle between the line drawn from the center of humeral head along the longitudinal axis of the scapular body, and the line drawn from the center of humeral head to the center of the bicipital groove, measured on the axial PDW images (Figure 2d).

The following qualitative variables were assessed in the images:

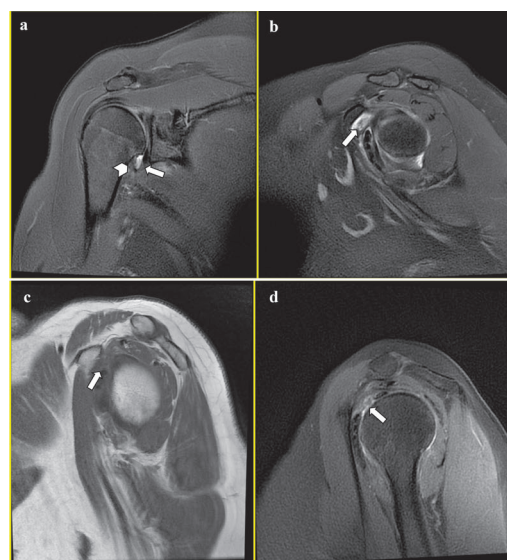

**Figure 2.** Quantitative variables of interest, as measured by the radiologists. (a) Maximum axillary capsular thickness, measured on oblique coronal proton-density weighted MRI of a 54-year-old female with adhesive capsulitis. (b) Humeral and glenoid axillary capsule thickness, measured on the same picture as "a". (c) Coracohumeral ligament thickness, measured on oblique sagittal proton-density weighted MRI of a 64-year-old female diagnosed with adhesive capsulitis. (d) Maximum degree of external rotation, measured on axial proton-density weighted MRI of a healthy 56-year-old female.

- Anterior capsular abnormal signal intensity, defined as an increased signal of the capsule on fat-suppressed PDW images.
- Axillary recess capsular abnormal signal intensity, defined as an increased signal of the capsule at any point of the axillary recess on fat-suppressed PDW images (Figure 3a).
- Glenoid capsular abnormal signal intensity, defined as an increased signal of the glenoid side of axillary recess capsule on fat-suppressed PDW images (Figure 3a).
- Humeral capsular abnormal signal intensity, defined as an increased signal of the humeral side of axillary recess capsule on fat-suppressed PDW images (Figure 3a).
- Sub-coracoid fat abnormal signal intensity, defined as any amount of fluid signal in the fat on fat-suppressed PDW images (Figure 3b).
- Obliteration of the sub-coracoid fat, defined as complete replacement of the fat with soft tissue signal on T1W images (Figure 3c).
- Rotator interval capsular abnormal signal intensity, defined as an increased signal of the capsule in the rotator interval, on fat-suppressed PDW images (Figure 3d).

#### Statistical analysis

The quantitative variables were reported in terms of mean  $\pm$  SD, and the qualitative variables in terms of percentage of



**Figure 3.** Qualitative variables of interest, as assessed by the radiologists. a. Oblique coronal proton-density weighted MRI of a 56-year-old female in the adhesive capsulitis group shows abnormal edema signal along the humeral (arrowhead) and glenoid (arrow) sides of axillary capsule. b. Oblique sagittal proton-density weighted MRI of the same patient in "a" shows fluid signal in the subcoracoid fat (arrow). c. Oblique sagittal T1weighted MRI of a 64-year-old female in the adhesive capsulitis group depicts complete obliteration of the subcoracoid fat (arrow). d. Oblique sagittal proton-density weighted MRI in a 56-year-old female with adhesive capsulitis demonstrates abnormal edema signal along the rotator interval capsule (arrow).

frequency. The quantitative and qualitative variables were compared between cases and controls, by independent t-test and chi square, respectively. P-value of 0.05 was chosen as the level of significance. For the significantly different variables, sensitivity, specificity, positive and negative predictive values and accuracy were calculated.

Receiver operator characteristic (ROC) curve analysis was conducted on the quantitative variables, to determine the optimum cut-off values and compare their diagnostic performances.

Inter-observer agreement was calculated, by Gamma (Goodman and Kruskal's gamma) Coefficient for quantitative, and Cohen's Kappa coefficient for qualitative variables, respectively. All statistical analyses were performed, using SPSS version20 (Chicago, IL, USA).

## Results

Mean  $\pm$  SD for age of the cases and controls was  $51.7 \pm 6.6$  and  $48.9 \pm 10.9$  years, respectively, and no significant difference existed in the mean age between the two groups ( $P=0.23$ ). Cases included 18 females (60%) and 12 males (40%) and controls included 16 females (53.3%) and 14

males (46.7%), which did not show significant difference among the groups ( $P=0.23$ ).

All analyzed quantitative and qualitative variables, showed significant difference between the two groups ( $P<0.001$ ). Table 1 summarizes the mean and standard deviation for the quantitative variables. Table 2 summarizes the percent of frequency for the qualitative variables.

Table 3 shows the sensitivity, specificity, positive and negative predictive values and accuracy of diagnosis of the qualitative MRI criteria. The abnormal signal of anterior capsule, along with the abnormal capsular signal at axillary recess and rotator interval were the most accurate qualitative criteria. The anterior capsular abnormal signal was the most specific criterion; similar to obliteration of the sub-coracoid fat (both with 100% specificity). Abnormal signal of the capsule in axillary recess showed to be the most sensitive.

Optimum cut-off values and diagnostic performances of the quantitative variables, through ROC analysis (Figures 4 and 5), are summarized in Table 4. Coracohumeral ligament and anterior capsule thicknesses with cut-off points of 2.45 mm and 1.3 mm respectively, showed

**Table 1.** Mean and standard deviation of the quantitative variables

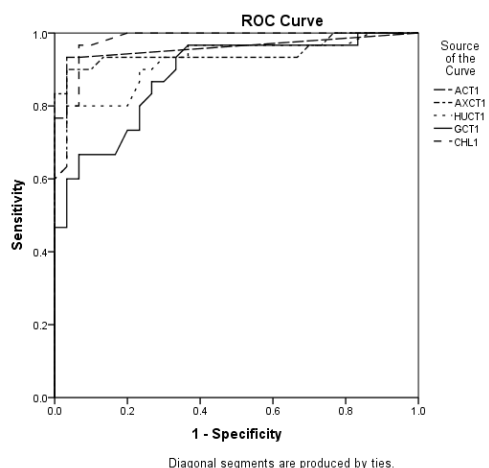
Criteria	Control		Case		P value
	Mean	SD	Mean	SD	
Anterior capsular thickness	0.4	0.3	2.4	1	<0.001
Axillary capsular thickness	5.8	1.6	12.5	3	<0.001
Humeral capsular thickness	2.6	1.2	6.1	2.2	<0.001
Glenoid capsular thickness	3.1	1.3	5.7	1.7	<0.001
Coracohumeral ligament thickness	1.5	0.6	4.7	1.8	<0.001
Degree of external rotation	154.4	11.6	137.6	14.1	<0.001

**Table 2.** Frequency of the qualitative variables

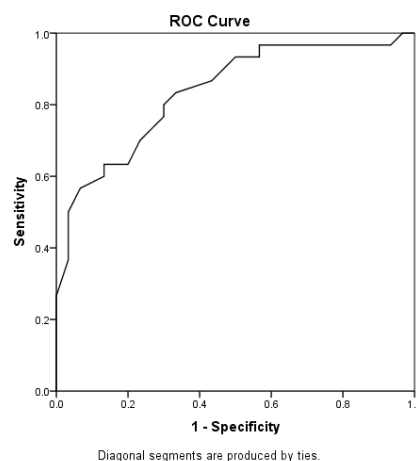
Criteria	Control		Case		P value
	No.	%	No.	%	
Anterior capsule abnormal signal	0	0	24	80	<0.001
Axillary capsule abnormal signal	1	3.3	27	90	<0.001
Humeral capsule abnormal signal	1	3.3	24	80	<0.001
Glenoid capsule abnormal signal	0	0	23	76.7	<0.001
Subcoracoid fat abnormal signal	4	13.3	26	86.7	<0.001
Obliteration of subcoracoid fat	0	0	12	40	<0.001
Rotator interval abnormal signal	0	0	25	83.3	<0.001

**Table 3.** Diagnostic performance of the qualitative variables

Statistic	Rotator interval abnormal signals	Obliteration of subcoracoid fat	Subcoracoid fat abnormal signal	Glenoid capsule abnormal signal	Humeral capsule abnormal signal	Axillary capsule abnormal signal	Anterior capsule abnormal signal
Sensitivity	83.3%	40%	86.7%	76.7%	80%	90%	80%
Specificity	96.7%	100%	86.7%	100%	96.7%	96.7%	100%
Positive predictive value	96.2%	100%	86.7%	100%	96%	96.4%	100%
Negative predictive value	85.3%	62.5%	86.7%	81.1%	82.9%	90.6%	83.3%
Accuracy	90%	70%	86.7%	88.3%	88.3%	93.3%	90%



**Figure 4.** Receiver operator characteristic (ROC) curve for the quantitative variables.



**Figure 5.** Receiver operator characteristic (ROC) curve for “Degree of external rotation”.

the greatest area under curve, indicative of the highest diagnostic performance of these criteria.

Inter-observer agreement results were subcategorized to 1.0: perfect agreement, 0.81–0.99: near perfect agreement, 0.61–0.80: substantial agreement, 0.41–0.60: moderate agreement, 0.21 – 0.40: fair agreement and  $\leq 0.20$ : slight agreement (10). Table 5 summarizes the degree of agreement for all the assessed variables. All quantitative variables, showed near perfect agreement between the observers, with the anterior capsular thickness being the mostly agreed upon criterion (gamma coefficient: 0.98). All qualitative variables showed perfect agreement among the observers, except abnormal signal of the subcoracoid fat and glenoid capsule of the axillary recess (with kappa’s coefficient: 0.87 and 0.85 respectively).

### Discussion

Regarding its prevalence and debilitating nature, adhesive capsulitis has long been a subject of study; with many of them being focused on MRI criteria for diagnosis of the disease.

Studies dated from 2000 to 2018, in summary, were focused on these criteria, on non-contrast MRI: coracohumeral ligament thickness, capsular/synovial thickening in axillary recess, abnormal signal intensity of axillary recess capsule and inferior glenohumeral ligament in fluid-sensitive sequences, obliteration of the subcoracoid fat, distension of the subscapularis recess, and effusion in the long head of biceps tendon sheath (11-17).

A meta-analysis performed by Suh et al on 2019 ultimately suggested that thickening of the coracohumeral

**Table 4.** Diagnostic performance of the quantitative variables

Statistic	Degree of external rotation	Coracohumeral ligament thickness	Glenoid capsular thickness	Humeral capsular thickness	Axillary capsular thickness	Anterior capsular thickness
Area under curve	0.836	0.978	0.885	0.922	0.946	0.959
Cut-off (mm)	146.5	2.45	4.11	4.5	8.3	1.3
Sensitivity	70%	96.7%	80%	80%	90%	86.7%
Specificity	80%	93.3%	76.7%	96.7%	96.7%	96.7%
Positive predictive value	77.8%	93.5%	77.4%	96%	96.4%	96.3%
Negative predictive value	72.7%	96.6%	79.3%	82.9%	90.6%	87.9%

**Table 5.** Inter-observer agreement for quantitative and qualitative variables

Qualitative variable	Kappa coefficient	Category	Quantitative variable	Gamma coefficient	Category
Anterior capsule abnormal signal	1	Perfect	Anterior capsular thickness	0.980	Near perfect
Axillary capsule abnormal signal	1	Perfect	Axillary capsular thickness	0.967	Near perfect
Humeral capsule abnormal signal	1	Perfect	Humeral capsular thickness	0.952	Near perfect
Glenoid capsule abnormal signal	0.850	Near perfect	Glenoid capsular thickness	0.913	Near perfect
Subcoracoid fat abnormal signal	0.877	Near perfect	Coracohumeral ligament thickness	0.966	Near perfect
Obliteration of subcoracoid fat	1	Perfect	Degree of external rotation	0.919	Near perfect
Rotator interval abnormal signal	1	Perfect			

ligament was the most specific, while enhancement of the axillary recess and rotator interval were the most sensitive MRI criteria of adhesive capsulitis. The latter two criteria were assessed in contrast-enhanced images, which were not included in our study, due to the fact that contrast-enhanced MRI is not usually performed in the approach to shoulder pain in practice (18).

Rotator interval of the shoulder was first introduced by Neer in 1970 as a shoulder stabilizer (19). Since then, many studies were focused on changes of this space and its structures in the course of adhesive capsulitis. The relative complexity of its anatomy and small size of the structures, make it difficult to evaluate the rotator interval on imaging and arthroscopy. The coracohumeral ligament and sub-coracoid fat are the only easily recognizable structures of this space on non-contrast MRI, and that is the reason why studies based on conventional shoulder MRI, were focused on these two criteria (20).

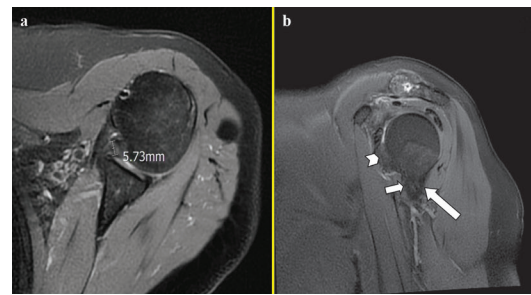
From 2019 on, some authors proposed new quantitative criteria, aiming to suggest a way of more accurate and practical evaluation of the rotator interval, on non-contrast images, which include the width of rotator interval, coracohumeral ligament area, thickness of rotator interval soft tissue and the superior glenohumeral ligament thickness (21-23).

In 2019, Park et al introduced the concept of anterior capsule of the shoulder for the first time, and evaluated its thickness and signal intensity in a case-control study, the results of which showed a significant difference of both variables between the groups (7).

Anterior capsule of the shoulder was defined as the glenohumeral capsule from 2-5 O'clock, which is supported by the middle and spiral glenohumeral ligaments. The spiral glenohumeral ligament is attached to the lesser tubercle of humerus proximally and the infraglenoid tubercle distally. In the middle of its course the spiral glenohumeral ligament, passes in close proximity of the middle glenohumeral ligament and it blends with the inferior glenohumeral ligament at the end (7).

In the present study, thickening and abnormal signal of anterior capsule, both were significantly more frequent in adhesive capsulitis patients, in comparison with the controls. Given the cut-off point of 1.3 mm, anterior capsular thickness was 86.7% sensitive and 96.7% specific. With the area under curve equal to 0.95, anterior capsular thickness showed the highest diagnostic performance only after coracohumeral ligament thickness. One of the patients had normal axillary recess capsule and coracohumeral ligament thicknesses, while showing an anterior capsule thicker than the cut-off (5.7 mm). This means that if we would not have measured the anterior capsular thickness for this patient, the diagnosis of adhesive capsulitis was not made on MRI (Figure 6).

Our results were in congruence with the study by Park et al. The only significantly different finding was the mean of the anterior capsular thickness in patients, between



**Figure 6.** A 55-year-old female, with the final diagnosis of adhesive capsulitis. a. Axial proton-density weighted MRI shows thickening and edema of the anterior capsule of glenohumeral joint (calipers). b. Thickening and edema of the anterior joint capsule are also evident in this oblique sagittal proton-density weighted image (arrowhead). Note “within normal limit” thickness and signal intensity of the anterior (short arrow) and posterior (long arrow) bands of the inferior glenohumeral ligament.

the two studies (2.5 mm in ours versus 3.99 mm in the study by Park et al). The different imaging protocol and measuring method may be the cause; additional possible reasons include (a) Difference in disease pathogenesis course between the genetically different study populations. (b) Difference in the stage of the disease in the study population (7).

The abnormal signal of the anterior capsule, in conjunction with obliteration of the sub-coracoid fat and glenoid capsule abnormal signal showed to be 100% specific, which means that if either criterion exists, the diagnosis of adhesive capsulitis will be made confidently on MRI.

Another noteworthy point was the near perfect inter-observer agreement of anterior capsular thickness-actually the highest among our quantitative variables - which suggests that this criterion is acceptably clear for the inexperienced radiologist, to measure reliably.

Similarly, all other studied variables were significantly different between cases and controls, among which the coracohumeral ligament thickness was the most sensitive. This means that a thickness less than 2.45mm on MRI excludes adhesive capsulitis almost confidently. These findings are similar to those of Chi et al (24).

## Conclusion

Anterior capsule thickness and signal, as two reliable and reproducible criteria, are of significant value to be added to our routine MRI measurements, for diagnosis of adhesive capsulitis. Future studies with large sample volumes, clinical sub-categorization of the patients and multivariate analysis are recommended to more accurately define the role of anterior capsule, in MRI-based diagnosis of adhesive capsulitis.

## Limitations of the study

The current study faced with some limitations: (a) Small sample size, as most of our adhesive capsulitis patients did not undergo MR examination. (b) We did not sub-

categorize our patients based on the clinical stage, due to their small number. Studies with larger sample volumes are necessary to correlate the anterior capsular thickness with the clinical stage. (c) The gold standard of adhesive capsulitis was clinical-radiologic diagnosis, just the way it happens in practice. As most of the patients with adhesive capsulitis undergo conservative treatment, we did not have histopathologic prove to their diagnosis, and this makes our results prone to possible bias.

#### Authors' contribution

Conceptualization: MM. Methodology: MM. Formal analysis and investigation: SK. Resources: SK. Data Curation: SK. Writing- original draft preparation: SK. Writing- review and editing: MM, MA, NB. Visualization: SK. Supervision: MM. Project Administration: MM.

#### Ethical issues

The research followed the tenets of the Declaration of Helsinki. The Biomedical Research Ethics Committee, Tehran University of Medical Sciences approved this study (IR.TUMS.IKHC.REC.1400.008). This study was extracted from "Medical specialist degree" thesis of "Samin Khoei" at this university. Besides, this study was an observational, case-control, with informed consent being waived, due to its retrospective nature.

#### Conflicts of interest

The authors declare that they have no competing interests.

#### Funding/Support

This research did not receive any specific grant from funding agencies in the public, commercial, or not-for-profit sectors.

#### References

- Ewald A. Adhesive capsulitis: a review. *Am Fam Physician*. 2011; 83: 417-422.
- Ryan V, Brown H, Minns Lowe CJ, Lewis JS. The pathophysiology associated with primary (idiopathic) frozen shoulder: A systematic review. *BMC Musculoskelet Disord*. 2016;17:340. doi: 10.1186/s12891-016-1190-9.
- Chellathurai A, Subbiah K, Elangovan A, Kannappan S. Adhesive capsulitis: MRI correlation with clinical stages and proposal of MRI staging. *Indian J Radiol Imaging*. 2019;29:19-24. doi: 10.4103/ijri.IJRI\_116\_18.
- Sofka CM, Ciavarra GA, Hannafin JA, Cordasco FA, Potter HG. Magnetic resonance imaging of adhesive capsulitis: correlation with clinical staging. *HSS J*. 2008;4:164-9. doi: 10.1007/s11420-008-9088-1.
- Ramirez J. Adhesive Capsulitis: Diagnosis and Management. *Am Fam Physician*. 2019;99:297-300.
- Park YH, Park YS, Chang HJ, Kim Y. Correlations between MRI findings and outcome of capsular distension in adhesive capsulitis of the shoulder. *J Phys Ther Sci*. 2016;28:2798-2802. doi: 10.1589/jpts.28.2798.
- Park J, Choi YH, Chai JW, Cha SW, Lim JH, Jo CH, et al. Anterior capsular abnormality: another important MRI finding for the diagnosis of adhesive capsulitis of the shoulder. *Skeletal Radiol*. 2019;48:543-552. doi: 10.1007/s00256-018-3064-8.
- Yoon MA, Hong SJ, Hong S, Kang CH, Kim BH, Kim IS. The Association between the Magnetic Resonance Imaging Findings of Adhesive Capsulitis and Shoulder Muscle Fat Quantification Using a Multi-Echo Dixon Method. *Korean J Radiol*. 2018;19:63-71. doi: 10.3348/kjr.2018.19.1.63.
- Bang YS, Park J, Lee SY, Park J, Park S, Joo Y, et al. Value of Anterior Band of the Inferior Glenohumeral Ligament Area as a Morphological Parameter of Adhesive Capsulitis. *Pain Res Manag*. 2019;2019:9301970. doi: 10.1155/2019/9301970.
- Park S, Lee DH, Yoon SH, Lee HY, Kwack KS. Evaluation of Adhesive Capsulitis of the Shoulder With Fat-Suppressed T2-Weighted MRI: Association Between Clinical Features and MRI Findings. *AJR Am J Roentgenol*. 2016;207:135-141. doi: 10.2214/AJR.15.15200.
- Gondim Teixeira PA, Balaj C, Chanson A, Lecocq S, Louis M, Blum A. Adhesive capsulitis of the shoulder: value of inferior glenohumeral ligament signal changes on T2-weighted fat-saturated images. *AJR Am J Roentgenol*. 2012;198:W589-596. doi: 10.2214/AJR.11.7453.
- Fields BKK, Skalski MR, Patel DB, White EA, Tomasian A, Gross JS, et al. Adhesive capsulitis: review of imaging findings, pathophysiology, clinical presentation, and treatment options. *Skeletal Radiol*. 2019;48:1171-84. doi: 10.1007/s00256-018-3139-6.
- Connell D, Padmanabhan R, Buchbinder R. Adhesive capsulitis: role of MR imaging in differential diagnosis. *Eur Radiol*. 2002;12:2100-6. doi: 10.1007/s00330-002-1349-7.
- Yoon JP, Chung SW, Lee BJ, Kim HS, Yi JH, Lee HJ, et al. Correlations of magnetic resonance imaging findings with clinical symptom severity and prognosis of frozen shoulder. *Knee Surg Sports Traumatol Arthrosc*. 2017;25:3242-50. doi: 10.1007/s00167-015-3887-y.
- Hsu JE, Anakwenze OA, Warrender WJ, Abboud JA. Current review of adhesive capsulitis. *J Shoulder Elbow Surg*. 2011;20: 502-14. doi: 10.1016/j.jse.2010.08.023.
- Lefevre-Colau MM, Drape JL, Fayad F, Rannou F, Diche T, Minvielle F, et al. Magnetic resonance imaging of shoulders with idiopathic adhesive capsulitis: reliability of measures. *Eur Radiol*. 2005;15:2415-22. doi: 10.1007/s00330-005-2830-x.
- Carbone S, Napoli A, Gumina S. MRI of adhesive capsulitis of the shoulder: distension of the bursa in the superior subscapularis recess is a suggestive sign of the pathology. *Eur J Radiol*. 2014;83:345-8. doi: 10.1016/j.ejrad.2013.10.017.
- Suh CH, Yun SJ, Jin W, Lee SH, Park SY, Park JS, et al. Systematic review and meta-analysis of magnetic resonance imaging features for diagnosis of adhesive capsulitis of the shoulder. *Eur Radiol*. 2019;29:566-577. doi: 10.1007/s00330-018-5604-y.
- Neer CS 2nd. Displaced proximal humeral fractures: part I. Classification and evaluation. 1970. *Clin Orthop Relat Res*. 2006;442:77-82. doi: 10.1097/01.blo.0000198718.91223.ca.
- Petchprapa CN, Beltran LS, Jazrawi LM, Kwon YW, Babb JS, Recht MP. The rotator interval: a review of anatomy, function, and normal and abnormal MRI appearance. *AJR Am J Roentgenol*. 2010;195:567-76. doi: 10.2214/AJR.10.4406.
- Jung JH, Kim DH, Yi J, Kim DH, Cho CH. Determination of magnetic resonance imaging criteria for diagnosis of adhesive capsulitis. *Rheumatol Int*. 2019;39:453-460. doi: 10.1007/s00296-018-04238-9.
- Cho HR, Cho BH, Kang KN, Kim YU. Optimal Cut-Off Value of the Coracohumeral Ligament Area as a Morphological Parameter to Confirm Frozen Shoulder. *J Korean Med Sci*. 2020;35:e99. doi: 10.3346/jkms.2020.35.e99.
- Akkaya H, Soker E, Dilek O, Soker G, Gulek B. Evaluation of magnetic resonance imaging findings in adhesive capsulitis: which quantitative findings are most valuable? *Rev Assoc Med Bras (1992)*. 2021;67:1719-1723. doi: 10.1590/1806-9282.20210808.
- Chi AS, Kim J, Long SS, Morrison WB, Zoga AC. Non-contrast MRI diagnosis of adhesive capsulitis of the shoulder. *Clin Imaging*. 2017;44:46-50. doi: 10.1016/j.clinimag.2017.04.002.