



Evaluation of nestin expression in melanoma, basal cell carcinoma and basosquamous carcinoma

Mojgan Mokhtari¹, Negar Safari¹

Department of Pathology, Isfahan University of Medical Sciences, Isfahan, Iran

*Correspondence to

Negar Safari, Email:
Negarsafari2016@gmail.com

Received 29 June 2022

Accepted 28 Sep. 2022

Published online 9 Feb. 2023

Keywords: Nestin, Melanoma, Basal cell carcinoma, Basosquamous carcinoma, Skin cancer

Abstract

Introduction: Nestin plays a significant role in diagnosis, prognosis, clinical course and/or response to the treatment. Previous studies have investigated the nestin expression in melanoma, however a limited number have focused on basal cell carcinoma (BCC) and basosquamous carcinoma (BSC).

Objectives: The current study aimed to investigate nestin expression in melanoma, BCC, and BSC.

Materials and Methods: This cross-sectional study was conducted on 40 melanomas, 40 BCC and 40 BSC specimens. Tumor size, lesion location and stage of disease were recorded. Then, nestin staining was conducted in all the present samples, then the amount of nestin expression was assessed.

Results: According to the results of this study, nestin was expressed in all melanoma specimens; while it was expressed in 15% of BSC and 25% of BCC specimens. The mean score of nestin expression in melanoma specimens (0.85 ± 2.50) was significantly higher than the BSC and BCC specimens with the means of 0.36 ± 0.15 and 0.44 ± 0.25 respectively (P value < 0.001). However, there was no significant difference between BSC and BCC specimens in nestin expression. Additionally, in the melanoma specimens, a significant and direct relationship between nestin expression and the various stages of melanoma with the coefficient of 0.345 (P value = 0.025).

Conclusion: The results of the current study showed that expression of nestin could have a good prognostic value in skin melanoma while, there is a significant relationship with its progression. However, in non-melanoma specimens, no distinction can be detected regarding the nestin expression.

Citation: Mokhtari M, Safari N. Evaluation of nestin expression in melanoma, basal cell carcinoma and basosquamous carcinoma. Immunopathol Persa. 2023;x(x):e34431. DOI:10.34172/ipp.2023.34431.

Introduction

The name nestin is originated from the term neural stem cell protein. This protein consists of 1621 amino acids, which are usually present in two forms of 220-kDa glycosylated and one 177-kDa deglycosylated variant (1,2), that was basically discovered in the mice growing nervous system. This protein considered as a member of type VI intermediate filament (IF) (3,4). Nestin is actually a marker of neural progenitors and stem cells. There is a strong association between its expression and cell proliferation in the central nervous system (CNS). This protein is also expressed in a variety of other cells which can be conducted as a diagnostic and possibly prognostic marker of tumor malignancy due to its expression in many types of solid human tumors (4,5).

Nestin has been found in neuroectodermal (neuroepithelial) tumour, including astrocytic, oligodendroglial, oligoastrocytic, ependymal, embryonic, and neuronal tumors. The nestin expression has been observed in mesenchymal tumors, germ cell tumors and epithelial tumors (6-9).

In some types of tumors, an association

Key point

This study was conducted on 40 melanomas, 40 basal cell carcinoma (BCC) and 40 basosquamous carcinoma (BSC) specimens. The nestin staining was conducted in all of the samples, then the amount its expression was assessed. The results of this study showed that mean expression of nestin in melanoma specimens was significantly higher than the BSC and BCC specimens however; there was no significant difference between BSC and BCC.

between increased nestin expression and tumor grade and disease prognosis indicating an immature and invasive phenotype of altered cells were detected (10). Several studies have reported the relationship between nestin expression in tumor tissue and a poor prognosis of breast carcinoma, ovarian carcinoma, gastrointestinal tumors, germ cell tumors, osteosarcoma, ependymoma, and melanoma (11-15). It can also be considered as a marker to assess the poor treatment response in multiple myeloma (16).

Therefore, it seems that nestin plays a role in the diagnosis, prognosis, clinical

course and also the treatment response of some tumors. Previous studies have investigated nestin expression in melanoma; however, very limited studies have put under consideration its expression in basal cell carcinoma (BCC) and basosquamous carcinoma (BSC) (17,18).

Objectives

Besides, fewer studies have compared the three samples of melanoma, BCC, and BSC, the present study was carried out to compare the nestin expression in melanoma, BCC, and BSC.

Materials and Methods

Study design

In this cross-sectional study, the samples were obtained from various melanoma, basal and basosquamous cell carcinomas blocks available in the storage unit of Al-Zahra hospital, which have been stored until the end of 2020.

Using the compression ratio formula and considering the frequency of nestin expression in BCC and melanoma in previous studies (17,19) as 48.1% and 82.4%, respectively, sample size was estimated as 120 specimens (40 specimens in each group). The sampling method was convenience that used for the patients listed in the hospital files.

First 40 specimens of melanoma, BCC, and BSC samples were collected, then sections with a thickness of 4 μm from each paraffin block were first placed on slides coated with APES (3-aminopropyltriethoxysilane) and stained for nestin. Sections were deparaffinized using xylene and rehydrated in graded alcohol. Recovery of antigens was conducted through heating the slides in citrate buffer (pH 6.0) in a pressure cooker. The endogenous peroxidase activity was then inhibited by placing the slides in 3% hydrogen peroxide for 10 minutes then the sections were placed in a 1:100 dilution solution of primary mouse

monoclonal nestin antibody for 2 hours. At the next step, the slides were washed and immersed in biotin for 10 minutes and horseradish peroxidase enzyme was applied at the following 10 minutes, then the slides were washed finally. Freshly prepared and dyed diaminobenzidine was conducted to determine the antibody binding site. Finally, the sections were stained with Mayer hematoxylin and observed under the light microscope (20).

Nestin staining was examined in all available areas. The cells presenting brown staining in the cytoplasm were considered positive for nestin. Stained sections were scored based on the percentage of stained cells in three fields with 400 \times magnification. This score was determined based on the method proposed in the literatures (21). Score zero (negative); no staining or staining less than 5% of cells, score +1 (mild); 5%-15% staining of tumor cells, score +2 (moderate); staining of 16%-25% of tumor cells, and score +3 (severe); staining of more than 25% of tumor cells (Figures 1 and 2).

It should be noted that the information including the age, gender, tumor size, subtype, clark level, disease stage, skin lesion location, original sample, or metastasis were also extracted from the patients' files and registered in the checklist of each sample.

Statistical analysis

Finally, the collected data were analyzed by SPSS software (version 26) and presented as mean \pm standard deviation (SD) or number (percent). Besides, independent *t* test was used for comparing the mean of quantitative variables between the three groups and one-way analysis of variance (ANOVA) for pair-wise comparison of groups. Tukey post hoc test, chi-square test and Fisher's exact test were conducted for comparing the frequency distribution of qualitative data between the three groups. A significance

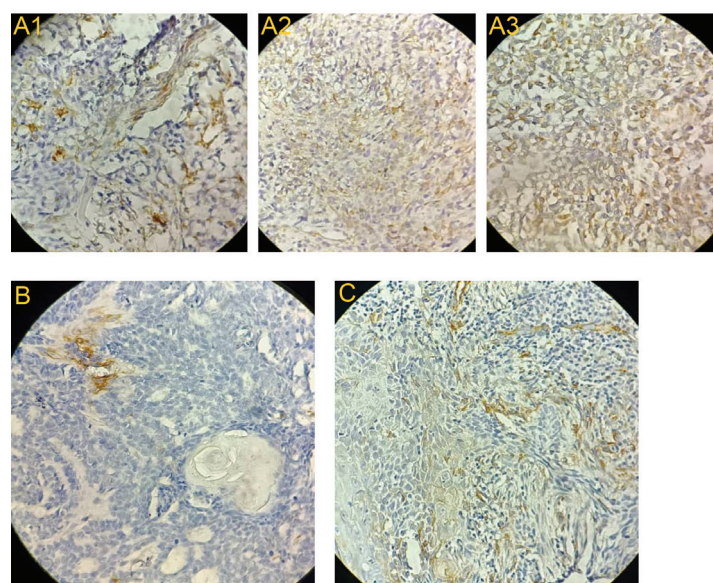


Figure 1. Positive nestin expression by immunohistochemistry in melanoma (A1: expression +1, A2: expression 2+, A3: expression 3+), basal cell carcinoma (BCC) (B: Negative expression) and basosquamous carcinoma (BSC) (C: expression 1+) samples.

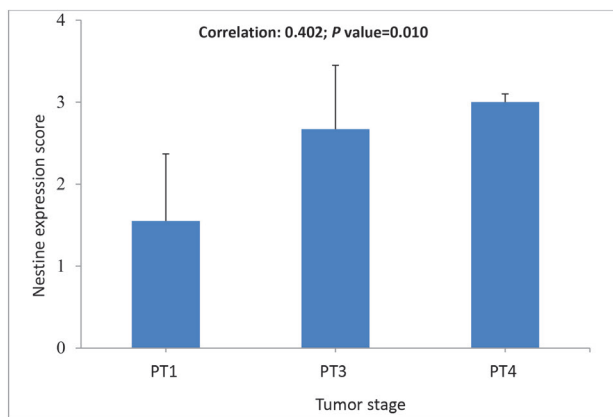


Figure 2. Bar graph of the mean nestin expression according to tumor stage in the melanoma specimens.

level of less than 0.05 was considered in all analyzes.

Results

In the current study, melanoma specimens of 25 (62.5%) men and 15 (37.5%) women with skin cancer and the mean age of 63.95 ± 18.81 years were evaluated. There were 24 (60%) BSC specimens in men and 16 (40%) cases in women with the mean age of 66.00 ± 15.63 years, and 40 BCC specimens in 21 (52.5%) men and 19 cases (47.5%) in women with the mean age of 66.68 ± 7.63 years (P value >0.05 ; Table 1).

In melanoma specimens, there was 52.5% nodular, 37.5% lentigo maligna and in BCC specimens, there was 60% nodular, 20% superficial, 5% adenoid, and 5% infiltrative. The tumor location in all three types of specimens was most frequent in the head and neck, while none of the BCC specimens was found in the lower and upper limbs (Table 2).

In addition, the tumor thickness in the melanoma specimens was 3.12 ± 2.25 mm since the Clark level percentage of II, III, IV and V levels was 12 cases (30%), 8

cases (20%), 16 cases (40%), and 4 cases (10%), respectively. Tumor stage in this specimen was PT1 in 11 cases (27.5%), PT3 in 12 cases (30%), PT4 in 12 cases (30%), PT4b in 4 cases (10%) and it was not recorded in 5 cases (12.5%).

Nestin expression in melanoma specimens with the mean of 2.50 ± 0.85 was significantly more than BSC and BCC specimens (0.15 ± 0.36 and 0.25 ± 0.44 , respectively; $P < 0.001$); however, the mean of BSC and BCC specimens did not show a significant difference in terms of nestin expression ($P = 0.449$). According to the frequency distribution of nestin expression, it was detected in all melanoma specimens with the highest expression rate in 72.5% of melanoma specimens. While in BSC and BCC specimens it was 15% and 25%, respectively, and the recorded expression showed a score of +1 (very mild) ($P < 0.001$). In addition, in the melanoma specimens, a significant and direct relationship between nestin expression and different stages with a correlation coefficient of 0.402 ($P = 0.010$; Table 3, Figures 1 and 2) was seen.

It should be noted that in melanoma subtypes, nestin expression in nodular with the mean of 2.90 ± 0.30 was significantly higher than lentigo maligna with the mean of 1.80 ± 1.01 ($P < 0.001$).

Discussion

According to the results of the present study, frequency distribution of skin cancer was higher in males than females without any significant difference. Moreover, the mean age of the patients with this cancer is mostly over 60 years. It also seems that the prevalence of skin cancer in the head and neck is higher than the other areas of the body.

In this regard, epidemiological studies have reported the skin cancer as the most common cancer in humans. The two main types of skin cancer are non-melanoma (BCC, BSC), and melanoma cancers. It should be noted that men are

Table 1. Comparison of age and gender of skin cancer patients in three types of tissue specimens

Characteristics		Melanoma (n=40)	BSC (n=40)	BCC (n=40)	P
Gender, No. (%)	Male	25 (62.5)	24 (60.0)	21 (52.5)	0.640
	Female	15 (37.5)	16 (40.0)	19 (47.5)	
Age (y), Mean \pm SD		63.95 ± 18.81	66.00 ± 15.63	66.68 ± 7.63	0.693

Table 2. Comparison of tumor information in three tissue types of specimens under study

Variables		Melanoma (n = 40)	BSC (n = 40)	BCC (n = 40)
Sample type	The main tissue	37 (92.5)	38 (95)	40 (100)
	Metastatic tissue	3 (7.5)	2 (5)	0 (0)
Tumor location	Head and neck	19 (47.5)	30 (75)	37 (92.5)
	Body	4 (10)	0 (0)	3 (7.5)
	Upper limb	4 (10)	2 (5)	0 (0)
	Lower limbs	13 (32.5)	8 (20)	0 (0)

Table 3. Comparison of nestin expression in three types of tissue specimens

Nestin expression	Melanoma (n=40)	BSC (n=40)	BCC (n=40)	P1	P2	P3
Nestin score	2.50 ± 0.85	0.15 ± 0.36	0.25 ± 0.44	<0.001	<0.001	0.449
Nestin score	0	0 (0%)	34 (85%)	<0.001	<0.001	0.264
	+1	9 (22.5%)	6 (15%)			
	+2	2 (5%)	0 (0%)			
	+3	29 (72.5%)	0 (0%)			

0: no staining or staining less than 5% of cells, +1 (mild): 5-15% staining of tumor cells, +2 (moderate): Staining of 16-25% of tumor cells, and +3 (severe): Staining of more than 25% of tumor cells.

P1: Significant level of comparison between melanoma and BSC samples.

P2: Significant level of comparison between melanoma and BCC samples.

P3: Significant level of comparison between BCC and BSC samples.

less involved in preventive behaviors that leads to a higher prevalence among them (22). According to the results of previous studies, melanoma is the second most common tumor among men and the third most common tumor in women (23). On the other hand, life style, ultraviolet (UV) exposure and aging are the important factors in the incidence of skin cancer, therefore its prevalence was more common in the seventies and eighties and lowest among the group of younger than 10 years (24).

Nestin expression in melanoma specimens was significantly more than two fold of non-melanoma specimens (BSC and BCC); however, there was no significant difference between BSC and BCC specimens. In other words, nestin expression was positive in melanoma specimens, but its expression in both BSC and BCC specimens was only 15% and 25%, respectively (the expression rate in this number was equal to 1).

Therefore, it can be stated that nestin expression in the prognosis of skin melanoma is significantly more valuable than non-melanoma skin cancers. In addition, the prognostic value of this expression in non-melanoma specimens cannot be distinctive.

Abbas and Bhawan conducted a study on 51 specimens, including 11 Merkel cell carcinoma, 20 BCC and 20 SCC specimens to investigate the expression of nestin in cutaneous malignancies. They indicated that BCC and Merkel cell carcinoma were negative in terms of nestin expression, while its expression was positive in 45% of SCCs (25). It can be said that their research findings were consistent with our findings; regarding no significant nestin expression that was found in BCC specimens. However, in their work, expression of nestin in SCC was significantly higher than BCC specimens. Although SCC was not examined in our study, nestin expression was generally of little value in the BSC. This expression will not be valuable in the basosquamous specimen, and due to the lack of study on this specimen (BSC) it has been discussed with more caution.

In addition, Fusi et al found that expression of nestin in the peripheral blood of healthy individuals was negative, while in patients with melanoma, it was observed in a portion of melanoma cells isolated from peripheral blood and tissue samples, but it had no significant difference in

various stages of the disease (26).

There are many other studies reporting poor expression of nestin in the tissues of such tumors as melanoma skin cancer, breast carcinoma, ovarian cancer, gastrointestinal tumors, germ cells, ependymoma, etc with a poor but thought-provoking prognosis and it is necessary to do large cohort studies to achieve more definite results (11-15).

Akiyama et al investigate nestin expression in malignant melanoma and nevus and they have suggested a significant relationship with melanoma and disease progression. Given its expression in nevus, nestin is probably an important marker for melanocytic neoplasms (19). This study reported that the cell growth, migration, invasion, and sphere-forming ability in vitro and tumor growth and partially metastasis in vivo decreased with reduction of nestin expression in melanoma cells through alteration of the expression pattern of F-actin and regulation of the MAPK pathway. Therefore, nestin can be considered as a therapeutic candidate for malignant melanoma (19).

Another research on the expression of nestin and some other markers in differentiating Trichoblastoma from BCC reported lack of any significant difference between trichoblastoma and BCC in this process (17). As previously mentioned, the BSC specimens has been used in the present work, but it was not used in the mentioned study. However, the authors also reported no significance in nestin expression in the BCC specimens, which is similar to our study.

Evaluation of two non-melanoma specimens (BSC and BCC) along with melanoma specimens of skin cancer can be considered as the strength of the current study. However, small sample size and lack of evaluation of disease progression and the relationship between nestin expression and disease progression in different specimens can be regarded as weaknesses of this work. In addition, due to the limited number of samples related to other melanocytic tumors (such as blue nevus, Spitz nevus and reed nevus) in the pathology department of Al-Zahra hospital, it was not possible to evaluate and compare the expression of nestin markers among these tumors. Considering that the disease progression can be associated with higher mortality, it seems that further studies are

needed for evaluating the prognostic value of nestin expression in different specimens of this cancer and its relationship with disease progression and treatment. It is also noteworthy that the early diagnosis of high stage and grade cases, as well as early determination of the disease prognosis in the direction of proper treatment approach prevents wasting time, increases life expectancy, and thus, maintains efficient human resources in society.

Conclusion

The results of the present study indicated that nestin was expressed in the all of skin cancer melanoma specimens. Moreover, in the melanoma specimens it was significantly higher than BCC and BSC specimens. Additionally, two non-melanoma skin cancer specimens were very weak in terms of nestin expression and did not differ significantly. Finally, it was found that there is a direct and significant relationship between nestin expression and different stages in melanoma specimens. Hence, it seems that nestin expression can provide an acceptable prognostic value in melanoma skin cancer tissue specimens and their progression.

Limitations of the study

The small sample size and lack of evaluation of disease progression and the relationship between nestin expression and disease progression in different specimens can be regarded as weaknesses of our work

Authors' contribution

Conceptualization: NS and MM.

Methodology: NS and MM.

Validation: NS and MM.

Formal analysis: NS.

Investigation: NS and MM.

Resources: MM.

Data curation: NS and MM.

Writing—original draft preparation: NS and MM.

Writing—review and editing: NS and MM.

Visualization: NS and MM.

Supervision: MM.

Project administration: NS and MM.

Funding acquisition: NS.

Conflicts of interest

The authors declare that they have no competing interests.

Ethical issues

The research followed the tenets of the Declaration of Helsinki. The Ethics Committee of Isfahan University of Medical Sciences approved this study (IR.MUI.MED.REC.1399.1040). Accordingly, written informed consent was taken from all participants before any intervention. This study was extracted from M.D/MSc thesis of Negar Safari at this university (Thesis #399944). Besides, ethical issues (including plagiarism, data fabrication and double publication) have been completely observed by the authors.

Funding/Support

This work supported by deputy research and technology of Isfahan University of Medical Sciences (Grant # 399944).

References

- Dahlstrand J, Zimmerman LB, McKay RD, Lendahl U. Characterization of the human nestin gene reveals a close evolutionary relationship to neurofilaments. *J Cell Sci.* 1992;103:589-97. doi: 10.1242/jcs.103.2.589.
- Lobo MV, Arenas MI, Alonso FJ, Gomez G, Bazán E, Paño CL, et al. Nestin, a neuroectodermal stem cell marker molecule, is expressed in Leydig cells of the human testis and in some specific cell types from human testicular tumours. *Cell Tissue Res.* 2004;316:369-76. doi: 10.1007/s00441-003-0848-4.
- Hockfield S, McKay RD. Identification of major cell classes in the developing mammalian nervous system. *J Neurosci.* 1985;5:3310-28. doi: 10.1523/JNEUROSCI.05-12-03310.1985.
- Lendahl U, Zimmerman LB, McKay RD. CNS stem cells express a new class of intermediate filament protein. *Cell.* 1990;60:585-95. doi: 10.1016/0092-8674(90)90662-x.
- Lee JH, Park HS, Shin JM, Chun MH, Oh SJ. Nestin expressing progenitor cells during establishment of the neural retina and its vasculature. *Anat Cell Biol.* 2012;45:38-46. doi: 10.5115/acb.2012.45.1.38.
- Krupkova O Jr, Loja T, Zambo I, Veselska R. Nestin expression in human tumors and tumor cell lines. *Neoplasma.* 2010;57:291-8. doi: 10.4149/neo_2010_04_291.
- Ishiwata T, Matsuda Y, Naito Z. Nestin in gastrointestinal and other cancers: effects on cells and tumor angiogenesis. *World J Gastroenterol.* 2011;17:409-18. doi: 10.3748/wjg.v17.i4.409.
- Dela Cruz FS. Cancer stem cells in pediatric sarcomas. *Front Oncol.* 2013;3:168. doi: 10.3389/fonc.2013.00168.
- Sterlacci W, Savic S, Fiegl M, Obermann E, Tzankov A. Putative stem cell markers in non-small-cell lung cancer: a clinicopathologic characterization. *J Thorac Oncol.* 2014;9:41-9. doi: 10.1097/JTO.000000000000021.
- Ehrmann J, Kolár Z, Mokry J. Nestin as a diagnostic and prognostic marker: immunohistochemical analysis of its expression in different tumours. *J Clin Pathol.* 2005;58:222-3. doi: 10.1136/jcp.2004.021238.
- Qin Q, Sun Y, Fei M, Zhang J, Jia Y, Gu M, et al. Expression of putative stem marker nestin and CD133 in advanced serous ovarian cancer. *Neoplasma.* 2012;59:310-5. doi: 10.4149/neo_2012_040.
- Sakurada K, Saino M, Mouri W, Sato A, Kitanaka C, Kayama T. Nestin expression in central nervous system germ cell tumors. *Neurosurg Rev.* 2008;31:173-6. doi: 10.1007/s10143-007-0115-3.
- Zambo I, Hermanova M, Adamkova Krakorova D, Mudry P, Zitterbart K, Kyr M, et al. Nestin expression in high-grade osteosarcomas and its clinical significance. *Oncol Rep.* 2012;27:1592-8. doi: 10.3892/or.2012.1687.
- Nambirajan A, Sharma MC, Gupta RK, Suri V, Singh M, Sarkar C. Study of stem cell marker nestin and its correlation with vascular endothelial growth factor and microvascular density in ependymomas. *Neuropathol Appl Neurobiol.* 2014;40:714-25. doi: 10.1111/nan.12097.
- Sabet MN, Rakhshan A, Erfani E, Madjd Z. Co-expression of putative cancer stem cell markers, CD133 and Nestin, in skin tumors. *Asian Pac J Cancer Prev.* 2014;15:8161-9. doi: 10.7314/apjcp.2014.15.19.8161.
- Svachova H, Kryukov F, Kryukova E, Sevcikova S, Nemeč P, Greslikova H, et al. Nestin expression throughout multistep pathogenesis of multiple myeloma. *Br J Haematol.* 2014;164:701-9. doi: 10.1111/bjh.12689.
- Leblebici C, Bambul Sığircı B, Kelten Talu C, Koca SB, Huq GE. CD10, TDAG51, CK20, AR, INSM1, and Nestin

- Expression in the Differential Diagnosis of Trichoblastoma and Basal Cell Carcinoma. *Int J Surg Pathol.* 2019;27:19-27. doi: 10.1177/1066896918781719.
18. Misago N, Mori T, Narisawa Y. Nestin expression in stromal cells of trichoblastoma and basal cell carcinoma. *J Eur Acad Dermatol Venereol.* 2010;24:1354-8. doi: 10.1111/j.1468-3083.2010.03641.x.
 19. Akiyama M, Matsuda Y, Ishiwata T, Naito Z, Kawana S. Inhibition of the stem cell marker nestin reduces tumor growth and invasion of malignant melanoma. *J Invest Dermatol.* 2013;133:1384-7. doi: 10.1038/jid.2012.508.
 20. Singh KN, Ramadas MN, Veeran V, Naidu MR, Dhanaraj TS, Chandrasekaran K. Expression Pattern of the Cancer Stem Cell Marker "Nestin" in Leukoplakia and Oral Squamous Cell Carcinoma. *Rambam Maimonides Med J.* 2019;10:e0024. doi: 10.5041/RMMJ.10378.
 21. Ravindran G, Devaraj H. Prognostic significance of neural stem cell markers, Nestin and Musashi-1, in oral squamous cell carcinoma: expression pattern of Nestin in the precancerous stages of oral squamous epithelium. *Clin Oral Investig.* 2015;19:1251-60. doi: 10.1007/s00784-014-1341-z.
 22. Schrom KP, Kim I, Baron ED. The Immune System and Pathogenesis of Melanoma and Non-melanoma Skin Cancer. *Adv Exp Med Biol.* 2020;1268:211-226. doi: 10.1007/978-3-030-46227-7_11.
 23. Bellenghi M, Puglisi R, Pontecorvi G, De Feo A, Carè A, Mattia G. Sex and Gender Disparities in Melanoma. *Cancers (Basel).* 2020;12:1819. doi: 10.3390/cancers12071819.
 24. Apalla Z, Lallas A, Sotiriou E, Lazaridou E, Ioannides D. Epidemiological trends in skin cancer. *Dermatol Pract Concept.* 2017;7:1-6. doi: 10.5826/dpc.0702a01.
 25. Abbas O, Bhawan J. Expression of stem cell markers nestin and cytokeratin 15 and 19 in cutaneous malignancies. *J Eur Acad Dermatol Venereol.* 2011;25:311-6. doi: 10.1111/j.1468-3083.2010.03791.x.
 26. Fusi A, Ochsenreither S, Busse A, Rietz A, Keilholz U. Expression of the stem cell marker nestin in peripheral blood of patients with melanoma. *Br J Dermatol.* 2010;163:107-14. doi: 10.1111/j.1365-2133.2010.09779.x.