



Mastitis as a rare inflammatory manifestation of brucellosis in human; a case report

Nasrin Ghiasi¹, Samira Barjasteh², Naser Gharebagh³, Rohollah Valizadeh⁴, Amin Safaripour^{5*}

¹Department of Midwifery, Faculty of Medicinal Sciences, Ilam University of Medical Sciences, Ilam, Iran

²Nursing and Midwifery School, Tehran University of Medical Sciences, Tehran, Iran

³Department of Infectious Diseases, Urmia University of Medical Sciences, Urmia, Iran

⁴Student Research Committee, School of Public Health, Iran University of Medical Sciences, Tehran, Iran

⁵Student Research Committee, Faculty of Medicine, Urmia University of Medical Sciences, Urmia, Iran

*Correspondence to

Amin Safaripour,

Email:

safaripouramin@gmail.com

Received 2 March 2019

Accepted 23 March 2019

Published online 17 April 2019

Keywords: Breast, Brucellosis, Mastitis

Abstract

Brucellosis leads to some systemic symptoms in humans but breasts are rarely affected, while it has frequently in animals. Brucellosis is endemic in Iran. A 30-year-old lady, living in rural area in West Azerbaijan, with fever, trembling and inflammation on the one side of left breast referred to infectious clinic of Taleghani hospital. The patient declared that had fever, weakness, arthritis and loss of appetite 1 week prior to the visit. Ultrasound was requested and showed mastitis. Antibiotics in beta-lactam groups had no effect on the patient. Serology tests, Wright, Coombs-Wright and 2-mercaptoethanol (2ME) was positive with the titer of 1/640, 1/1280 and 1/640, respectively. Treatment method was a combination of doxycycline, gentamicin and rifampin. The patient was under observation for 2 months until her ultrasound results changed to normal. It is concluded that the probability of *Brucella* mastitis should be considered as a differential diagnosis in endemic areas. Other differential diagnoses can be inflammatory carcinoma and simple mastitis.



Citation: Ghiasi N, Barjasteh S, Gharebagh N, Valizadeh R, Safaripour A. Mastitis as a rare inflammatory manifestation of brucellosis in human; a case report. *Immunopathol Persa*. 2019;5(1):e06. DOI:10.15171/ipp.2019.06.

Introduction

Brucellosis is a zoonotic, infectious and contagious disease caused by a gram-negative, non-motile and short rod in the family Brucellaceae (1). Most common symptoms of brucellosis consist of weakness, pyrexia, night sweats with peculiar odor and trembling (2). It should be noted that the prevalence of this zoonotic has led to more than 500 million cases in the world, as well as more than 500 000 new affected subjects annually (2).

Brucellosis similar to many diseases can be influenced by some factors such as socioeconomic status (3) and the involvement severity of society (4,5). Meanwhile, brucellosis is roughly forgotten bacterial worldwide (6). It imposes very heavy financial and health burden on the health systems in the many countries especially in the developing countries (3,6,7), and lies in the Middle-East countries, Iran, Egypt, Syria, Iraq, and Turkey (2,3, 8). There are different statistics regarding the brucellosis frequency in Iran. The incidence has reported between 98 and 130 per 100 000

Key point

The probability of *Brucella* mastitis should be considered as a differential diagnosis in the endemic areas. Other differential diagnoses can be inflammatory carcinoma and simple mastitis.

people (9). According to the reports, South of Iran has the lowest incidences causing high clinical morbidity and various clinical manifestations in humans and must be differentiated by meningitis, encephalitis, endocarditis, arthritis and spondylitis (10,11).

In addition, the incidence of this disease has a clear seasonal pattern, which is accompanied with a reduction in the production of agricultural products and livestock such as dairy products increasing the economic burden on the inhabitants of that area (12). Soft tissue infection is considered as an unusual manifestation of brucellosis in humans (13,14). We report a 30-year old lady with bilateral *Brucella* mastitis with breast inflammation caused by brucellosis.

Case Presentation

The patient was a 30-year-old resident of one of the villages of West Azerbaijan. She was illiterate and her job was animal husbandry. She had the history of night sweating, fever periods, weakness, arthralgia, backache, anorexia for two weeks. Although, β -lactam antibiotics were given for 10 days before admission, all symptoms were progressed. Therefore, she was admitted to the hospital. In her history, she explained that she had consumed fresh and unpasteurized dairy product before the initiation of her symptoms. On physical examination, breasts were swollen, red and stiff, particularly on the left side. Her temperature was 39°C. The respiratory and cardiac systems were normal (blood pressure; 130/80 mm Hg, respiratory rate; 18/min, pulse rate; 82/min). There was no localized mass in the stiff lymph nodes in each axillary area. Ultrasound revealed reduced echymosis of the glandular appendages in the retro-areolar region and lower intradermal quadrants. Ultrasonography diagnosis was mastitis (Figure 1). Serology tests, Wright, Coombs-Wright and 2-mercaptoethanol (2ME) was positive with the titer of 1/640, 1/1280 and 1/640, respectively. In laboratory tests, CBC, ESR (erythrocyte sedimentation rate) and CRP (C-reactive protein) were normal.

As a result of these radiological and laboratory findings, we diagnosed bilaterally Brucella mastitis in this patient. Rifampin 300 mg/d (once a day), doxycycline 100 mg/d (twice a day) and gentamicin 80 mg/d were started as anti-brucellosis treatment and continued for 8 weeks. The response of the treatment was observed after one week and the breasts returned to normal size and appearance by the end of the second week of treatment. After 8 weeks, the titer was 1/160. At controls, the ultrasonography and mammography findings were completely normal (Figure 2).

Discussion

Eastern Mediterranean is considered as a high-risk region for developing brucellosis in a way that approximately 500 000 cases of brucellosis are annually reported from countries in this region and the most important endemic area in the Eastern Mediterranean is Iran (15). The inflammation of breast and mastitis are common complications in animals, but it is reported as a rare condition in humans, while, there are a few cases of reported mastitis (16, 17).

Brucella mastitis in human occurs in non-lactation women, while more mastitis occurs in lactating women. (18,19). In contrast to our report, the most common form of breast infection is staphylococcal mastitis in humans, and Brucella mastitis is not primarily found in lactating women (20). A case was reported by Bayani et al (21) in Iran which the case of interest was a 67-year-old woman, living in a rural area in Babol city, Iran accompanied with fever, trembling and inflammation on one side of right breast, weakness, arthritis and loss of appetite from one

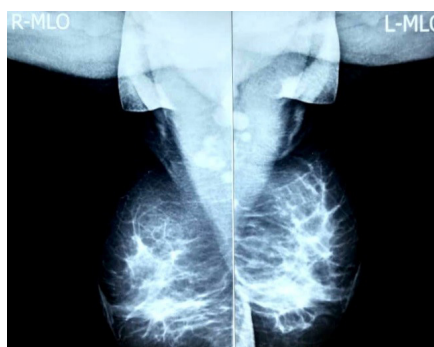


Figure 1. Ultrasonography of breasts indicating mastitis.

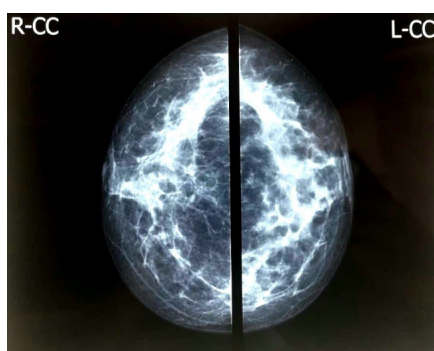


Figure 2. Ultrasonography of breasts indicating normal status.

week prior to the visit. This case report was similar to our report regarding symptoms and place of residence.

Likewise, Akay et al (16), in Turkey reported the case of a 52-year old woman with bilateral Brucella mastitis, which was difficult to differentiate from inflammatory breast carcinoma. Indeed, Brucella mastitis in terms of clinical findings and complications may cause difficulties in diagnosis (22,23) and may be difficult to diagnose due to non-specific manifestation and misinterpretation of in vitro tests (24,25).

In our study, given the fact that the patient was at the age of fertility and lactation, but the brucella mastitis was diagnosed. In this regard, it could be said that we reported a new case report. Also, due to the similarity of the symptoms of granulomatous mastitis and breast carcinoma in patients with swollen and inflamed breast, the differential diagnosis of these cases was also rejected. Given the fact that Iran is an endemic area of this disease, it can be considered as an important differential diagnosis, in such way that no case remains unidentified.

Conclusion

It is concluded that the probability of Brucella mastitis should be considered as a differential diagnosis in the endemic areas. Other differential diagnoses can be inflammatory carcinoma and simple mastitis.

Authors' contribution

Authors contributed equally to the manuscript.

Conflicts of interest

The authors report no conflicts of interest.

Ethical considerations

Ethical issues (including plagiarism, data fabrication, double publication) have been completely observed by the authors. The patient has given her informed consent regarding the publication of this case report.

Funding/Support

No internal or external source of funding was available.

References

1. Earhart K, Vafakolov S, Yarmohamedova N, Michael A, Tjaden J, Soliman A. Risk factors for brucellosis in Samarqand Oblast, Uzbekistan. *Int J Infect Dis.* 2009;13:749-53. doi: 10.1016/j.ijid.2009.02.014.
2. Pappas G, Papadimitriou P, Akritidis N, Christou L, Tsianos EV. The new global map of human brucellosis. *Lancet Infect Dis.* 2006;6:91-9. DOI: 10.1016/S1473-3099(06)70382-6.
3. Dean AS, Crump L, Greter H, Schelling E, Zinsstag J. Global burden of human brucellosis: a systematic review of disease frequency. *PLoS Negl Trop Dis.* 2012;6:e1865. doi: 10.1371/journal.pntd.0001865.
4. Kamal S, Sadat Hashemi SM, Nasaji M, Moshiri E, Shahriyari R, Azizi A. Frequency of reported cases of Brucellosis to province health center from public and private sectors in Semnan 2006-2007. *Koomesh.* 2009;10:125-30.
5. Kirk MD, Pires SM, Black RE, Caipo M, Crump JA, Devleeschauwer B, et al. World Health Organization estimates of the global and regional disease burden of 22 foodborne bacterial, protozoal, and viral diseases, 2010: a data synthesis. *PLoS Med.* 2015;12:e1001921. doi: 10.1371/journal.pmed.1001921.
6. Hotez PJ, Savioli L, Fenwick A. Neglected tropical diseases of the Middle East and North Africa: review of their prevalence, distribution, and opportunities for control. *PLoS Negl Trop Dis.* 2012;6:e1475. doi: 10.1371/journal.pntd.0001475.
7. Pakzad R, Pakzad I, Safiri S, Shirzadi MR, Mohammadpour M, Behroozi A, et al. Spatiotemporal analysis of brucellosis incidence in Iran from 2011 to 2014 using GIS. *Int J Infect Dis.* 2018;67:129-136. doi: 10.1016/j.ijid.2017.10.017.
8. Sofian M, Aghakhani A, Velayati AA, Banifazl M, Eslamifar A, Ramezani A. Risk factors for human brucellosis in Iran: a case-control study. *Int J Infect Dis.* 2008;12:157-61. doi: 10.1016/j.ijid.2007.04.019.
9. Roushan MRH, Ebrahimpour S. Human brucellosis: An overview. *Casp J Int Med.* 2015;6:46.
10. Shoraka H, Hosseini S, Safavizadeh A, Avaznia A, Rajabzadeh R, Hejazi A. Epidemiological study of brucellosis in Maneh & Semelghan town. North Khorasan province. *J North Khorasan Univ Med Sci* 2010; 2(2-3): 65-72.
11. Skendros P, Pappas G, Boura P. Cell-mediated immunity in human brucellosis. *Microbes Infect.* 2011;13:134-42.
12. Dean AS, Crump L, Greter H, Schelling E, Zinsstag J. Global burden of human brucellosis: a systematic review of disease frequency. *PLoS Negl Trop Dis.* 2012;6:e1865. doi: 10.1371/journal.pntd.0001865.
13. Gurleyik E. Breast abscess as a complication of human brucellosis. *Breast J.* 2006;12:375-6. doi: 10.1111/j.1075-122X.2006.00281.x.
14. Ibis C, Albayrak D, Yagci M. Bilateral brucellar breast abscess in a 48-year-old woman. *Ann Saudi Med.* 2009;29:158. doi: 10.4103/0256-4947.51793.
15. Mirnejad R, Jazi FM, Mostafaei S, Sedighi M. Molecular investigation of virulence factors of *Brucella melitensis* and *Brucella abortus* strains isolated from clinical and non-clinical samples. *Microb Pathog.* 2017;109:8-14. doi: 10.1016/j.micpath.2017.05.019.
16. Akay H, Girgin S, Ozmen C, Kilic I, Sakarya H. An unusual bilateral mastitis in a postmenopausal woman caused by brucellosis. *Acta Chir Belg.* 2007;107:320-2.
17. Orang R, Rouhi M, Sadegh Vahedi M, Kargar S, Taghipour Sh. Idiopathic granulomatous mastitis and arthralgia: a case report. *Iran J Breast Dis.* 2012;5:53-6.
18. Yu Z, Sun S, Zhang Y. High-Risk Factors for Suppurative Mastitis in Lactating Women. *Med Sci Monit.* 2018;24:4192-7. doi: 10.12659/MSM.909394.
19. Valente SA, Grobmyer SR. Mastitis and Breast Abscess. *Breast* 5th ed. Elsevier; 2018. p. 93-103. e2. doi:10.1016/B978-0-323-35955-9.00006-4.
20. Tewari M, Shukla HS. Breast tuberculosis: diagnosis, clinical features and management. *Indian J Med Res* 2005;122:103-10.
21. Bayani M, Ghaemian N, Izadpanah F. A Case Report of Mastitis due to *Brucella* Infection in Post-menopausal Woman. *J Isfahan Med Sch* 2014;32:1461-5.
22. Khan M, Zahoor M. An Overview of Brucellosis in Cattle and Humans, and its Serological and Molecular Diagnosis in Control Strategies. *Trop Med Infect Dis.* 2018;3:65. doi: 10.3390/tropicalmed3020065.
23. Mahmodlou R, Dadkhah N, Abbasi F, Nasiri J, Valizadeh R. Idiopathic granulomatous mastitis: dilemmas in diagnosis and treatment. *Electron Physician.* 2017;9:5375. doi: 10.19082/5375.
24. Jensenius M, Høiby EA, Stiris M, Berild D, Ringertz SH. Difficulties in diagnosing brucella-spondylitis. *Scand J Infect Dis* 2000;32:425-6. doi: 10.1080/003655400750045051.
25. Peiris V, Fraser S, Fairhurst M, Weston D, Kaczmarek E. Laboratory diagnosis of brucella infection: some pitfalls. *Lancet* 1992;339:1415-6.