



Budd-Chiari syndrome secondary to polycythemia vera with inferior vena cava thrombosis

Zain Majid*, Abbas Ali Tasneem, Nasir Hassan Luck, Muhammad Manzoor Ul Haque, Rajesh Kumar Mandhwani, Syed Mudassir Laeeq, Farina Muhammad Hanif, Ghulamullah Lail

Department of Hepatogastroenterology, Sindh Institute of Urology and Transplantation, Karachi, Pakistan

*Correspondence to

Zain Majid; Email: Zain88@hotmail.com

Received 17 April 2017

Accepted 29 June 2017

Published online 5 July 2017

Keywords: Budd Chiari Syndrome; Polycythemia vera; JAK2 mutation; Inferior vena cava thrombosis

Abstract

A middle aged male presented with abdominal distension since one month. Further workup showed plasma hemoglobin of 18.1 g/dL with a high pack cell volume (PCV), raised urea, creatinine and disturbed liver function tests. Abdominal ultrasonography showed an enlarged caudate lobe with thrombi in the inferior vena cava while CT scan of abdomen confirmed the same findings and was suggestive of Budd-Chiari syndrome. Further workup was conducted to rule out other causes and to find out the possible cause of Budd-Chiari syndrome. A peripheral film was requested, which showed hyper-segmented neutrophils. Later on JAK2 mutation and thrombophilia profile was ordered, which was positive for JAK2 mutation. Even though the patient was started on low molecular weight heparin but he eventually passed away.

Citation: Majid Z, Tasneem AA, Luck NH, Ul Haque MM, Mandhwani RK, Laeeq SM, et al. Budd-Chiari syndrome secondary to polycythemia vera with inferior vena cava thrombosis. *Immunopathol Persa*. 2018;4(1):e04. DOI: 10.15171/ipp.2018.04.

Introduction

Budd-Chiari syndrome is due to the obstruction of the hepatic efferent outflow tract from either the hepatic veins to where the inferior vena cava meets the right atrium (1). Its most frequent cause is polycythemia vera, a condition seen in around 10% to 40% of the diagnosed cases (1).

Case Presentation

A 40-year-old married male, visited the gastroenterology outpatient's department of our hospital having abdominal distension since the last one month. Initial workup revealed the following; hemoglobin 18.1 g/dL, pack cell volume (PCV) 52.5%, MCV 85 fL/red cell, total leukocyte count; $27000 \times 10^9/L$ and platelets of $510 \times 10^9/L$ and a INR of 2.1. Renal function tests showed a raised urea and creatinine (urea; 118 mg/dL and creatinine; 1.79 mg/dL), while his serum electrolytes were within normal limits. His liver function tests were deranged with total bilirubin of 5.5 mg/dL, direct bilirubin; 2.2 mg/dL, ALP; 132 U/L, SGPT; 111 U/L, SGOT; 55 U/L, GGT; 184 U/L. Moreover, his serum total proteins were raised, along with raised globulins of 5.2 g/dL.

His viral markers were negative and an ultrasound of whole abdomen showed an enlarged liver of 18 cm with a hypertrophied caudate lobe, hepatic veins were stenosed,

Key point

Budd-Chiari syndrome is due to the obstruction of the hepatic efferent outflow tract from either the hepatic veins to where the inferior vena cava meets the right atrium. Its pathogenesis is due to the decreased outflow of the liver, leading to increase in pressure, stasis and later on damage induced by hypoxia and thrombus in the portal veins.

having no flow and no branch of the hepatic veins was visualized. A partial thrombi was also noted in the inferior vena cava. Ascitic fluid analysis was carried out and a high SAAG ratio with a low ascitic protein was detected, along with an ascitic total leukocyte count of 250 with predominant neutrophils (70%). To further evaluation an esophagogastroduodenoscopy (EGD) was conducted, which revealed medium sized varices for which endovascular band ligation was done. Accordingly an ultrasound hepatic Doppler, revealed similar findings as shown by the ultrasound abdomen. To confirm the diagnosis of Budd-Chiari syndrome, abdominal CT scan was conducted, revealing an enlarged liver along with hypertrophy of caudate lobe, with non-opacification of the hepatic veins and a partial thrombus in the intrahepatic portion of the inferior vena cava (IVC) was noted (Figure 1). Portal vein



was mildly dilated and patent and spleen was enlarged measuring 13.3 cm. Additionally, serum alpha fetoprotein levels and serum TSH levels were also done which were within normal limits. All these findings were suggestive of Budd-Chiari syndrome. Meanwhile the patient was treated with low molecular weight heparin along with symptomatic management. A peripheral film was requested which revealed hyper-segmented neutrophils with panmyelosis findings which were suggestive of *JAK2* mutation. Later on a thrombophilia profile along with *JAK2* mutation test were ordered and a protein C and S deficiency was noted along with a positive *JAK2* mutation test. Since his PCV had decreased below 45% due to ongoing management and treatment, his phlebotomy sessions were deferred. During the hospital stay the patient's condition had been deteriorating day by day and despite being on low molecular weight heparin and having had abdominal paracentesis done a couple of times for his abdominal distension, the patient passed away.

Discussion

The actual incidence of Budd-Chiari syndrome is still not known but it is assumed to affect around one in a million people, mostly middle aged adults of either sex, mainly in the third to fourth decade of life (2). Its pathogenesis is due to the decreased outflow of the liver, leading to increase in pressure, stasis and later on damage induced by hypoxia and thrombus in the portal veins (3). Imaging modalities are commonly used to diagnose by an enlarged liver and caudate lobe and partial or non-visualization of the hepatic veins or intraluminal hyperechoic material also being noted. Hepatic Doppler ultrasound shows no or change in direction of blood flow (4). The onset of disease is variable and is dependent upon the speed of hepatic vein outflow occlusion (5). Polycythemia vera is a stem cell disease that is characterized by excess erythroid proliferation and is diagnosed using the WHO criteria, which is divided in major and minor criteria (6). Abut et al proposed ruling out possible pro-thrombotic conditions while evaluating the causes of Budd-Chiari syndrome (7). In the absence of a hepatic insult, anticoagulants along with diuretics are the main treatment for Budd-Chiari syndrome. However for a single localized obstruction, balloon angioplasty with stent placement can be done (8). Furthermore, Wang et al showed the importance of classifying patients of Budd-Chiari syndrome who have thrombi in their inferior vena cava, with interventional treatment being used for types I to III having acute thrombi and surgical shunts or a conservative approach with type III having an obsolete thrombi (9). For polycythemia vera, phlebotomy, myelosuppressive therapy or hydroxyurea along with other treatment modalities are used (1).

Conclusion

Our case highlights the need to consider polycythemia vera as one of the major cause of Budd-Chiari syndrome and that treatment for polycythemia vera should be started immediately, even when only a probably diagnosis

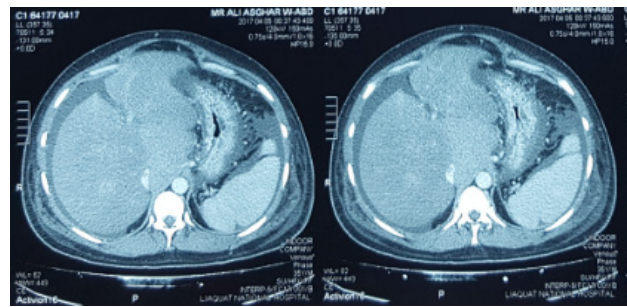


Figure 1. CT scan of the abdomen showing slightly irregular margins of the liver with ascites, hypertrophy of caudate lobe compressing the sub-hepatic inferior vena, non-opacification of the hepatic veins with a partial thrombus in the intrahepatic portion of the inferior vena cava.

is made, which could either be phlebotomy, hydroxyurea or myelosuppressive therapy. Since a delay could end up taking the patient's life.

Authors' contribution

All authors contributed equally to the work.

Conflicts of interest

The authors declare no conflicts of interest.

Ethical considerations

Ethical issues (including plagiarism, data fabrication, double publication) have been completely observed by the authors. Informed consent was obtained from the patient for publication as a case report.

Funding/Support

None.

References

1. Buzas C, Sparchez Z, Cucuianu A, Manole S, Lupescu I, Acalovschi M. Budd-Chiari syndrome secondary to polycythemia vera. A case report. *J Gastrointest Liver Dis.* 2009;18:363-6.
2. Budd-Chiari Syndrome [Internet]. Dove Med website. 2017 [cited 21 May 2017]. Available from: <http://www.dovemed.com/diseases-conditions/budd-chiari-syndrome/>.
3. Rajani R, Melin T, Björnsson E. Budd-Chiari syndrome in Sweden: epidemiology, clinical characteristics and survival - an 18-year experience. *Liver Int.* 2009;29:253-9.
4. Brancatelli G, Vilgrain V, Federle MP. Budd-Chiari syndrome: spectrum of imaging findings. *Am J Roentgenol.* 2007;188:W168-76.
5. Yoo EH, Jang JH, Park KJ. Prevalence of overt myeloproliferative neoplasms and *JAK2* V617F mutation in Korean patients with splanchnic vein thrombosis. *Int J Lab Hematol.* 2011; 33:471-6. doi:10.1111/j.1751-553X.2011.01308.x.
6. Polycythemia Vera: Practice Essentials, Pathophysiology, Epidemiology. Emedicine.medscape.com. 2017 [cited 30 May 2017]. Available from: <http://emedicine.medscape.com/article/205114-overview>.
7. Abut E, Güveli H, Kendir T, Bölükbaş C, Ince AT, Dalay AR, et al. A case of Budd-Chiari syndrome secondary to multiple thrombogenic conditions: a case report and review of literature. *Turk J Gastroenterol.* 2004;15:100-3.
8. Rav-Acha M, Gur C, Ilan Y, Verstandig A, Eid A. [Budd-Chiari syndrome: updated treatment modalities]. *Harefuah.* 2004; 143:372-6.
9. Wang R, Meng Q, Qu L, Wu X, Sun N, Jin X. Treatment of Budd-Chiari syndrome with inferior vena cava thrombosis. *Exp Ther Med.* 2013;5:1254-8. doi:10.3892/etm.2013.961.