



Treatment and management of CMV duodenitis in a patient with temporal arteritis

Zain Majid^{1*}, Shoab Ahmed¹, Raja Taha Yaseen¹, Rida Shahab¹, Muhammad Mubarak²

¹Department of Internal Medicine, Sindh Institute of Urology and Transplantation, Karachi, Pakistan

²Department of Histopathology, Sindh Institute of Urology and Transplantation, Karachi, Pakistan

*Correspondence to

Zain Majid;

Email: Zain88@hotmail.com

Received 7 April 2017

Accepted 19 May 2017

Published online 3 June 2017

Keywords: Elderly female, CMV duodenitis, Temporal arteritis, Azathioprine, Ganciclovir

Abstract

An elderly female, with a definitive diagnosis of temporal arteritis which was under treatment, referred to our hospital with weakness, epigastric pain along with oral ulcerations. Before admission, the patient had developed right sided throbbing headache along with decrease in vision of her right eye with an ESR of 72 mm/h. She was diagnosed as having temporal arteritis and was administered steroids and azathioprine. After a couple of months, patient started having generalized weakness, epigastric pain and oral ulceration and then her intake of solid food decreased. Patient was kept on liquid diet that was delivered by a nasogastric tube. Upper GI endoscopy along with biopsy revealed cytomegalovirus (CMV) duodenitis. She was started on oral ganciclovir and later her symptoms improved.

Citation: Majid Z, Ahmed S, Yaseen RT, Shahab R, Mubarak M. Treatment and management of CMV duodenitis in a patient with temporal arteritis. *Immunopathol Persa.* 2018;4(1):e02. DOI: 10.15171/ipp.2018.02.

Introduction

Temporal arteritis or giant cell arteritis, is a form of systemic vasculitis that occurs commonly in elderly people, having a wide array of presentation. In this case report, we describe a treatment and management of cytomegalovirus (CMV) duodenitis in a patient with temporal arteritis.

Case Report

An elderly female, known diabetic and hypertensive, being a diagnosed case of temporal arteritis, referred to outpatients' department with generalized weakness, epigastric pain, mouth ulcers and decreased appetite.

Around 8 months ago prior to symptom development, patient was involved by severe right sided throbbing headache along with decreased vision of the right eye which were not relieved by taking over the usual medications. Her further workup had revealed a raised erythrocyte sedimentation rate (ESR) of 72 mm/h. She was referred to a neurologist and after appropriated clinical evaluation, she was diagnosed as a case of temporal arteritis and then was treated with oral steroids and azathioprine.

After a period of 2-3 months, the patient developed generalized weakness, decreased appetite along with epigastric pain, oral

Key point

Our case shows that those patients on immunosuppressive therapy who developed GI symptoms should be evaluated for CMV infections.

thrush and mouth ulcerations. Treatment for oral thrush resulted in no relief of pain. The intake of solid food decreased and she was kept on liquid diet that was delivered by a nasogastric tube.

Upper GI endoscopy along with biopsy was planned and it showed mild fissuring of distal duodenum along with few erosions. The biopsy taken from the mucosa diagnosed it as a case of CMV duodenitis and gastritis (Figure 1).

She was started on oral ganciclovir that resulted in improvement of her symptoms and she was later discharged.

Discussion

Temporal arteritis or giant cell arteritis, regarded as a type of systemic vasculitis which occurs commonly in elderly people, having various presentations. Any new occurrence of headache in a patient who is older than 50 years of age and has a raised ESR should raise suspicion for it (1). It could affect the temporal (mainly),



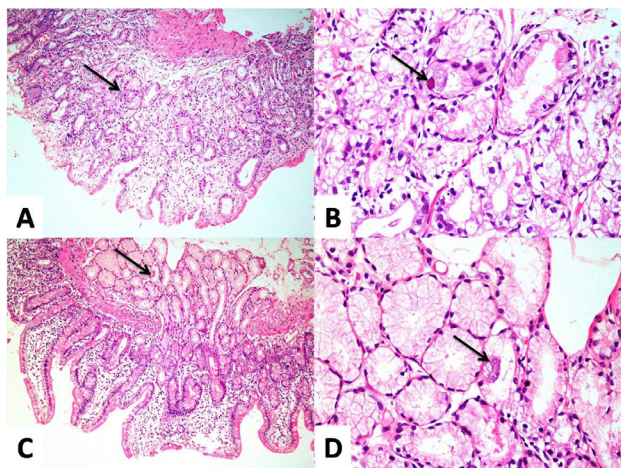


Figure 1. A. Low-power photomicrograph showing antral biopsy with mild inflammation and a cell with viral cytopathic effects (arrow) (HE, $\times 200$). B. High-power photomicrograph of the same biopsy showing characteristic nuclear and cytoplasmic viral inclusions (arrow) (HE $\times 400$). C. Low-power photomicrograph showing duodenal biopsy with mild mucosal inflammation and a cell with viral cytopathic effects in the submucosal glands (arrow) (HE $\times 200$). D. High-power photomicrograph of the duodenal biopsy showing characteristic cytoplasmic viral inclusions (arrow) (HE $\times 400$).

ophthalmic, vertebra, aorta and even the carotid arteries. Biopsy of the affected artery remains the gold standard in diagnosing it. Treatment revolves around steroid therapy, with cyclosporine, azathioprine and methotrexate being administered in resistant cases (1).

Immunosuppressive therapy (such as steroid treatment) may lead to upper GI infections by viruses. One such infection in an immunocompromised person is by the CMV (2).

CMV virus becomes symptomatic in a person having a compromised immune system and could involve virtually any organ of our body. In those who are HIV positive, its main manifestation is “CMV induced retinitis” but may also affect the entire GI system in them (3).

A CMV infected person excretes virus frequently. Virus transmission occurs through blood products, the placenta, sexual contact, organ transplantation or breast milk.

CMV's involvement of the GI system usually leads to a ulcerative lesion, with CMV gastritis presenting as abdominal pain and hematemesis while CMV colitis (CMV's main manifestation of the GI system) presenting as diarrhea in an infected individual (2,3).

Infections by CMV are also considered when a patient has more than one ulcer and various erosions in the gastroduodenal region (4).

In order to diagnose CMV infection of the GI system, the virus must be isolated from the mucosa of the GI tract as

shown in Figure 1.

CMV infection could be very severe in geriatric patients (4,5).

Such infections by CMV in those with a compromised immune system are usually treated with systemic antiviral therapy and if needed withdrawal of the immune suppressive drugs (2). This was also shown by Onaka et al, who demonstrated the effectiveness of intravenous ganciclovir to treat CMV gastroduodenitis (4).

Ahn et al showed the effectiveness of ganciclovir administered to treat CMV duodenitis in bone marrow transplant (BMT) patients, which led to the healing of the ulcer and relief from the symptoms within 3 weeks of treatment (6).

Conclusion

Our case shows that those patients on immunosuppressive therapy who developed GI symptoms should be evaluated for CMV infections.

Authors' contribution

All authors contributed equally to the work.

Conflicts of interest

The authors declare no conflicts of interest.

Ethical considerations

Ethical issues (including plagiarism, data fabrication, double publication) have been completely observed by the authors. Informed consent was obtained from the patient for publication as a case report.

Funding/Support

None.

References

1. Ninds.nih.gov. Bell's Palsy Fact Sheet: National Institute of Neurological Disorders and Stroke (NINDS) . 2015 [cited 24 May 2015]. Available from: http://www.ninds.nih.gov/disorders/bells/detail_bells.html.
2. Smith LA, Gangopadhyay M, Gaya DR. Catastrophic gastrointestinal complication of systemic immunosuppression. *World J Gastroenterol.* 2015;21:2542-5.
3. Cytomegalovirus. Medscape website. 2015 [cited 23 May 2015]. Available from: <http://emedicine.medscape.com/article/215702overview#aw2aab6b2b2aa>
4. Onaka T, Yonezawa A, Imada K. A case of cytomegalovirus gastroduodenitis in an immunocompetent adult. *Kansenshogaku Zasshi.* 2013;87:49-52. [Japanese].
5. Péter A, Telkes G, Varga M, Sárváry E, Kovalszky I. Endoscopic diagnosis of cytomegalovirus infection of upper gastrointestinal tract in solid organ transplant recipients: Hungarian single-center experience. *Clin Transplant.* 2004;18:580-4.
6. Ahn JH, Lee JH, Lee KH, Kim WK, Lee JS, Bahng H, et al. Successful treatment with ganciclovir for cytomegalovirus duodenitis following allogeneic bone marrow transplantation. *Korean J Intern Med.* 1999;14:91-4.