



Clinicopathological comparative study of C4d positive and negative cases of IgA nephropathy

Binu Mary Bose^{1*}, Lillykutty Pothan¹, Jayakumar Kavanakkattu Parameswaran², Usha Poothiade¹

¹Department of Pathology, Government Medical College, Kottayam, Kerala, India

²Department of Nephrology, Government Medical College, Kottayam, Kerala, India

Correspondence to

Binu Mary Bose, Email:
doc_binubose@yahoo.co.in

Received 12 June 2016

Accepted 28 July 2016

Published online 23 Aug. 2016

Keywords: IgA nephropathy,
Glomerular C4d, Tubular C4d,
Oxford classification

Abstract

Introduction: IgA nephropathy (IgAN) is thought to be the most common glomerulonephritis in the world.

Objectives: To compare the clinicopathological features in C4d positive and negative cases of IgAN patients with reference to Oxford classification.

Materials and Methods: This is a cross-sectional study in which all renal biopsies coming to department of pathology, government medical college, Kottayam from January 2013 to June 2014 were evaluated and analysed by H & E, PAS, Jones methenamine silver, Masson's trichrome and IF for IgA, IgG, IgM, C3 and C1q. IHC for glomerular and tubular C4d was conducted in cases confirmed as IgAN and compared with the clinical features (age, sex, hypertension, serum creatinine and 24 hours urine protein), IF and histology based on Oxford classification.

Results: out of 33 cases of IgAN males predominated (19/33). Mean age group was 32 years. IgA positivity was 1+ in 12.1%, 2+ in 57.6% and 3+ in 30.3%. Glomerular C4d positivity was observed in 63.6% cases and tubular C4d positivity in 66.7%. Out of the clinical features studied, only nephrotic range proteinuria showed significant association with glomerular C4d positive cases. Glomerular C4d positive patients showed a higher level of IgA and C3 positivity which was significant. Only tubular atrophy/interstitial fibrosis in Oxford classification showed significant association with glomerular C4d positivity.

Conclusion: As compared with many other studies, this study also showed significant association of glomerular C4d positivity with albuminuria and tubular atrophy/interstitial fibrosis. The study further investigates this aspect of IgAN.

Introduction

Glomerular diseases usually occur with two types of presentations, nephritic syndrome and nephrotic syndrome. IgA nephropathy (IgAN) is thought to be the most common glomerular disease in the world (1) and is defined by deposition of IgA in the mesangial area due to aberrant glycosylation (2) as confirmed by immunohistochemistry or by immunofluorescence. IgAN carries a varying prognosis from asymptomatic to end-stage renal disease (3,4) due to this variability in outcome many studies have been done to detect the clinical and histological features that predict the prognosis in IgAN. A new classification has been proposed for IgAN, the Oxford classification of IgAN which takes into account mainly four variables. Mesangial hypercellularity (M), endocapillary proliferation (E), segmental glomerulosclerosis (S), tubular atrophy/interstitial fibrosis (T), all of which are proven

Key point

In a study on 33 cases of IgA nephropathy (IgAN), we found significant association of glomerular C4d positivity with albuminuria and tubular atrophy/interstitial fibrosis.

to have independent prognostic significance (5-7).

Main pathway involved in the pathogenesis of IgAN is alternative pathway. It has been now shown that lectin pathway also plays an important role in pathogenesis of IgAN. C4d is an indicator of activation of lectin pathway (8). In the recent studies C4d has been implicated to have a negative prognostic value (9-11).

In southern part of India, Kerala, no studies has been performed, combining Oxford classification of IgAN and immunohistochemical marker C4d both of which are independent prognostic indicators in IgAN.

Citation: Bose BM, Pothan L, Parameswaran JK, Poothiade U. Clinicopathological comparative study of C4d positive and negative cases of IgA nephropathy. Immunopathol Persa. 2017;3(1):e02.



Here lies the importance of this study which compares the immunohistochemical positivity for C4d with Oxford classification of IgAN.

Objectives

To compare the clinicopathological features in C4d positive and negative cases of IgAN patients with reference to Oxford classification.

Materials and Methods

Study patients

This is a cross-sectional study done to analyze the comparison between C4d positive and negative cases of IgAN with respect to certain clinical and histological variables (based on Oxford classification). All renal biopsies coming in department of pathology from January 2013 to June 2014 are analysed by routine hematoxylin and eosin, periodic acid–Schiff (PAS), reticulin and Masson's trichrome stained sections and by immunofluorescence for IgA, IgG, IgM, C3 and C1q.

All cases with a diagnosis of IgAN, as confirmed by immunofluorescence, were included to the study. Around 33 patients with IgAN were evaluated in this study. The medical records were reviewed and the following information at the time of the renal biopsy was recorded: patient age, sex, presence or absence of hypertension (defined as blood pressure >140/90 mm Hg or the use of antihypertensive agents), 24-hour urine protein excretion, urine volume and serum creatinine level.

Definition of IgAN

IgAN was identified by the presence of IgA-dominant (more than or equal to 2+ intensity) within glomeruli, as shown by immunohistochemistry or immunofluorescence methods in the presence of negative intensity for C1q. According to this definition all confirmed cases of IgAN were selected and immunohistochemistry was done for the presence of C4d in each.

Mesangial hypercellularity, segmental glomerulosclerosis and adhesion, endocapillary proliferation, interstitial fibrosis and tubular atrophy were evaluated according to Oxford classification (6).

Extracapillary proliferation, global sclerosis and segmental sclerosis were calculated as percentage of the total number of glomeruli. Mesangial proliferation was scored as mild when there were less than six cells per mesangial area and moderate to severe when there were more than six cells per mesangial area. Interstitial fibrosis/tubular atrophy was evaluated semi-quantitatively, was scored T0 (involving <25% of the interstitium/tubule), T1 (25%–50% of the interstitium/tubule involved) or T2 (when present in >50% of the renal interstitium), and whichever variable is predominating, either tubular atrophy or interstitial fibrosis, that is taken for scoring.

C4d immunohistochemical staining was performed on 3-µm deparaffinized and rehydrated sections of formaldehyde fixed renal tissue, using pre-diluted rabbit polyclonal anti-human C4d (BioGenex, California, USA) as the an-

tibody. In order to block non-specific staining, antigen retrieval was performed in advance of slide treatment by pressure cooking (20 minutes at 1 bar, citrate buffer, pH 6.0). The detection system used was UltraVision Quanto Detection System (Thermo Scientific, California, USA) according to the following protocol; block endogenous peroxidase with 3% H₂O₂ in Triss buffered saline for 10 minutes, wash sections in Triss buffered saline, apply anti-C4d antibody for 30 minutes at room temperature, wash in Triss buffered saline, apply DAB chromogen for 5 minutes, wash sections in tap water for 10 minutes, counterstain with hematoxylin for 2 minutes, clear and mount with DPX.

C4d immunohistochemical staining was scored as negative (0) or positive (1).

Glomerular C4d staining

C4d staining was observed in both endothelial and mesangial cells. Glomerular C4d was defined positive when more than 50% of glomeruli staining were observed.

This staining was classified as 'global' when >50% of mesangial area was affected and 'segmental' when <50% of the mesangial area was positive for C4d.

Tubular C4d staining

Tubular basement membrane (TBM) C4d staining was considered to be present if more than half of the circumference of TBM was stained. Tubular epithelial staining was considered to be positive if the granular pattern of C4d staining was present. Additionally baseline clinical and laboratory data were recorded.

Ethical issues

The study was conducted in accordance with the Declaration of Helsinki, International Conference on Harmonization Good Clinical Practice guidelines, and local ethics committees. All study participants provided informed consent. The study was approved by the Ethics Committee and the Research Board of Government Medical College, Kottayam, Kerala, India.

Statistical analysis

SPSS version 16.0 software (Chicago, IL, USA) was used for statistical analysis. Results were expressed as mean ± standard deviation. The chi-squared test was used to compare qualitative values. Student's *t* test was used to compare normally distributed quantitative variables. All statistical tests are two-tailed. A *P* value <0.05 was considered to be statistically significant.

Results

Total renal biopsies received during the study period was 173 out of which 33 cases were confirmed as IgAN and was evaluated. Proportion of glomeruli in the biopsies ranged from 5 to 22 (with a mean of 10.12 ± 4.7). 19 (57.6%) were males and 14 (42.4%) were females. The mean age was 32.61 years, with a minimum age of 10 years and maximum age of 59 years. IgA positivity was 1+ in 3 patients

(12.1%), 2+ in 22 patients (57.6%) and 3+ in 8 patients (30.3%). C1q was absent in all cases. Glomerular C4d positivity was observed in 21 cases (63.6%). Tubular C4d positivity was observed in 22 cases (66.7%). The mean age of patients showing glomerular C4d positivity was 33.86 ± 15.7 years and tubular C4d positivity was 33.09 ± 15.8 years. Ten patients were males and 11 patients were females in glomerular C4d positive cases and 11 were males and 11 were females in tubular C4d positive cases. Out of the clinical variables studied, microscopic hematuria, macroscopic hematuria, edema, hypertension, elevated serum creatinine and urine albumin excretion had no

significant association with C4d positivity ($P > 0.05$). Nephrotic range proteinuria was observed in glomerular C4d positive cases and showed significant association (Table 1). Glomerular C4d positive patient showed a higher level of IgA and C3 positivity (Figure 1). Only tubular atrophy/interstitial fibrosis in Oxford classification showed significant association with glomerular C4d positivity (Figure 2). Presence of crescents or global sclerosis had no association with C4d positivity.

Discussion

In this study, out of all clinical variables studied only 24

Table 1. Clinical variables and C4d positivity

Clinical variables	Glomerular C4d positive (21)	P value	Tubular C4d positive (22)	P value
Mean age	33.86 years	0.541	33.09 years	0.8
Sex	M: 10 , F: 11	0.126	M: 11 , F: 11	0.213
Hematuria	63.6%	1	54.5%	0.296
Edema	55.6%	0.290	66.7%	1
Hypertension	68.8%	0.554	62.5%	0.73
24 hours urine protein	3.9 ± 2.1 g/day	0.047	3.37 ± 1.72 gm	0.897
Serum creatinine	3.15 ± 2 mg/dL	0.146	2.15 ± 1.6 gm%	0.275

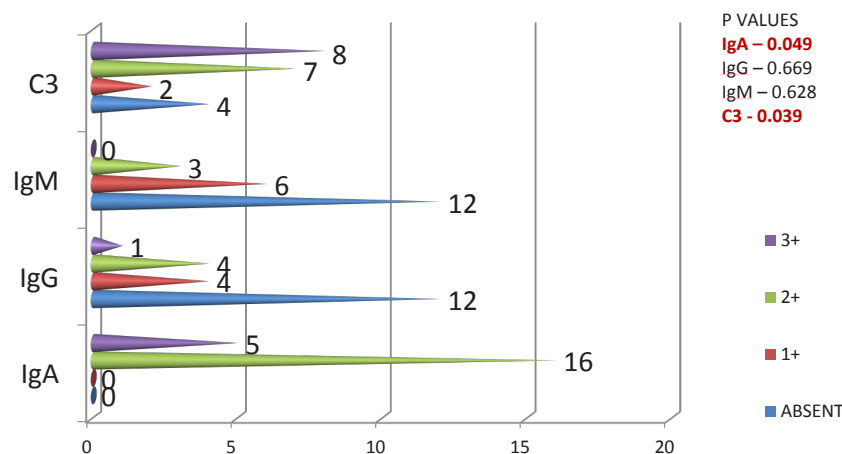


Figure 1. Glomerular C4d with immunofluorescence. (P values of intensity of positivity of IgA and c3 are less than 0.05).

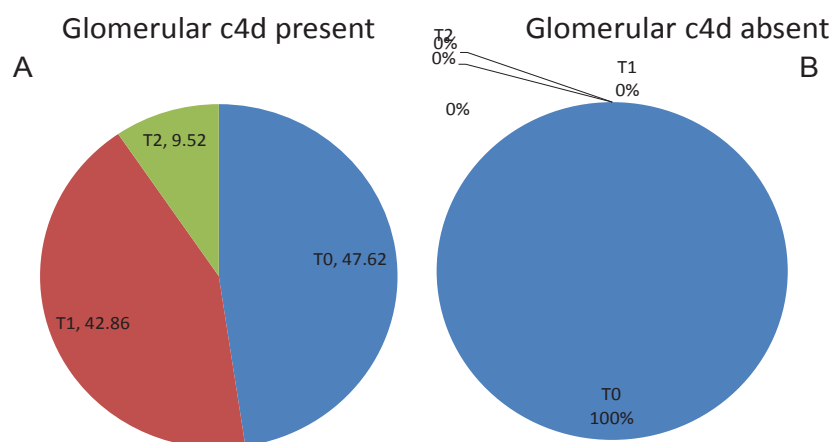


Figure 2. Glomerular C4d positivity with tubular atrophy/interstitial fibrosis (T). (A) P value – 0.009 , statistically significant. (B) Glomerular c4d positivity showed a significant association with tubular atrophy/interstitial fibrosis (T).

Table 2. C4d positivity and clinical variables; comparison among other studies

Variables	Espinosa et al	Sahin et al	Maeng et al	Present study
Gender (males)	74.6%	52.5%	-	57.6%
Age (years)	39.4	35.9	-	32.61
Hematuria	44.4%	50%	-	63.6%
Urine protein (Gm/day)	3 ± 1.9	3.9 ± 2.9	3.5 ± 1.4	3.9 ± 2.1
Serum creatinine (mg/dL)	2.6 ± 1.5	3.45±2.3	-	3.15±2.08

Table 3. Glomerular C4d with variables of Oxford classification

Variables	Espinosa et al	Sahin et al	Present study
Mesangial hypercellularity (<i>P</i> value)	0.4	0.0001	0.5
Endocapillary proliferation (<i>P</i> value)	-	0.09	1
Segmental glomerulosclerosis (<i>P</i> value)	0.01	0.004	0.17
Tubular atrophy/interstitial fibrosis (<i>P</i> value)	0.001	0.006	0.009

hours urine protein showed a significant association with glomerular C4d positivity which is comparable with other studies (Table 2). No studies has been conducted in this part of India to determine intensity of immunostaining of glomerular C4d with the renal outcome. Significant association of glomerular C4d with the intensity of IgA and C3 deposits was detected (Figure 1). Most of the studies established the association between segmental sclerosis and tubular atrophy/interstitial fibrosis, but in our study significant association is seen only with tubular atrophy/interstitial fibrosis (Table 3).

Conclusion

A possible association between the intensity of immunostaining (IgA, C3) with glomerular C4d has been proposed. However, since this is a descriptive study and sample size is small, further studies has to be done to prove this association.

Limitations of the study

Small proportion of the patients was the main limitation of study.

Aknowledgments

I aknowledge Ms. Kala Unnikrishnan for her tecnical assistance and valuable support in helping me with IHC and IF.

Authors' contribution

Study conception and design by BMB and LP. Acquisition of data by BMB and JKP. Analysis and interpretation of data by BMB and LP. Drafting of manuscript by BMB and LP. Critical revision by BMB, UP and LP.

Conflicts of interest

None to be declared.

Ethical considerations

Ethical issues (including plagiarism, data fabrication, double publication) have been completely observed by the authors.

Funding/Support

None.

References

- Espinosa M, Ortega R, Gomez-Carrasco JM, Lopez-Rubio F, Lopez-Andreu M, Lopez-Oliva MO, et al. Mesangial C4d deposition: a new prognostic factor in IgA nephropathy. *Nephrol Dial Transplant*. 2009;24:886-891.
- D'Amico G. Natural history of idiopathic IgA nephropathy and factors predictive of disease outcome. *Semin Nephrol*. 2004;24:179-96.
- Donadio j, Grande J. IgA Nephropathy. *N Engl J Med*. 2002;347:738-48
- Giannakakis K, Feriozzi S, Perez M, Faraggiana T, Muda AO. Aberrantly glycosylated IgA1 in glomerular immune deposits of IgA nephropathy. *J Am Soc Nephrol*. 2007;18:3139-46.
- Roberts IS, Cook HT, Troyanov S, Alpers CE, Amore A, Barratt J, et al. The Oxford classification of IgA nephropathy: pathology definitions, correlations, and reproducibility. *Kidney Int*. 2009;76:546-56.
- Cattran DC, Coppo R, Cook HT, Feehally J, Roberts IS, Troyanov S, et al. The Oxford classification of IgA nephropathy: rationale, clinicopathological correlations, and classification. *Kidney Int*. 2009;76:534-45.
- Katafuchi R, Ninomiya T, Nagata M, Mitsuiki K, Hirakata H. Validation study of oxford classification of IgA nephropathy: the significance of extracapillary proliferation. *Clin J Am Soc Nephrol*. 2011;6:2806-13.
- Maillard N, Wyatt RJ, Julian BA, Kiryluk K, Gharavi A, Fremeaux-Bacchi V, et al. Current understanding of the role of complement in iga nephropathy. *J Am Soc Nephrol*. 2015;26:1503-12.
- Cohen D, Colvin RB, Daha MR, Drachenberg CB, Haas M, Nickleit V, et al. Pros and cons for C4d as a biomarker. *Kidney Int*. 2012;81:628-39
- Maeng Y, Kim MK, Park JB, Cho CH, Oh HK, Sung WJ, et al. Glomerular and tubular C4d depositions in IgA nephropathy: relations with histopathology and with albuminuria. *Int J Clin Exp Pathol* 2013;6:904-10.
- Sahin OZ, Yavas H, Tasli F, Gibyeli DG, Ersoy R, Uzum A, et al. Prognostic value of glomerular C4d staining in patients with IgA nephritis. *Int J Clin Exp Pathol*. 2014;7:3299-304.